

University of Dundee

Evaluation of hyperspectral imaging (HSI) for the measurement of ischemic conditioning effects of the gastric conduit during esophagectomy

Köhler, Hannes ; Jansen-Winkeln, Boris ; Maktabi, Marianne ; Barberio, Manuel ; Takoh, Jonathan ; Holfert, Nico

Published in:
Surgical Endoscopy

DOI:
[10.1007/s00464-019-06675-4](https://doi.org/10.1007/s00464-019-06675-4)

Publication date:
2019

Document Version
Peer reviewed version

[Link to publication in Discovery Research Portal](#)

Citation for published version (APA):

Köhler, H., Jansen-Winkeln, B., Maktabi, M., Barberio, M., Takoh, J., Holfert, N., Moulla, Y., Niebisch, S., Diana, M., Neumuth, T., Rabe, S. M., Chalopin, C., Melzer, A., & Gockel, I. (2019). Evaluation of hyperspectral imaging (HSI) for the measurement of ischemic conditioning effects of the gastric conduit during esophagectomy. *Surgical Endoscopy*, 33(11), 3775-3782. <https://doi.org/10.1007/s00464-019-06675-4>

General rights

Copyright and moral rights for the publications made accessible in Discovery Research Portal are retained by the authors and/or other copyright owners and it is a condition of accessing publications that users recognise and abide by the legal requirements associated with these rights.

- Users may download and print one copy of any publication from Discovery Research Portal for the purpose of private study or research.
- You may not further distribute the material or use it for any profit-making activity or commercial gain.
- You may freely distribute the URL identifying the publication in the public portal.

Take down policy

If you believe that this document breaches copyright please contact us providing details, and we will remove access to the work immediately and investigate your claim.

Evaluation of hyperspectral imaging (HSI) for the measurement of ischemic conditioning effects of the gastric conduit during esophagectomy

Hannes Köhler², Boris Jansen-Winkel¹, Marianne Maktabi², Manuel Barberio^{1,3}, Jonathan Takoh¹, Nico Holfert¹, Yusef Moulla¹, Stefan Niebisch¹, Michele Diana³, Thomas Neumuth², Sebastian M Rabe¹, Claire Chalopin², Andreas Melzer², Ines Gockel¹

¹ Department of Visceral, Thoracic, Transplant and Vascular surgery, University Hospital of Leipzig, Germany

² Innovation Center Computer Assisted Surgery (ICCAS), University of Leipzig, Germany

³ Institute of Image-Guided Surgery (IHU), IRCAD, Strasbourg, France

Correspondence to:

Univ.-Prof. Dr. Ines Gockel, MBA

Department of Visceral, Transplant, Thoracic and Vascular Surgery

University Hospital of Leipzig

Liebigstr. 20

D-04103 Leipzig

GERMANY

Phone: +49/(0)341-9717211

Fax: +49/(0)341-9717209

Email: ines.gockel@medizin.uni-leipzig.de

Abstract

Background. Hyperspectral imaging (HSI) is a relatively new method used in image-guided and precision surgery, which has shown promising results for characterization of tissues and assessment of physiologic tissue parameters. Previous methods used for analysis of preconditioning concepts in patients and animal models have shown several limitations of application. The aim of this study was to evaluate HSI for the measurement of ischemic conditioning effects during esophagectomy.

Methods. Intraoperative hyperspectral images of the gastric tube through the mini-thoracotomy were recorded from n=22 patients, 14 of whom underwent laparoscopic gastrotomy and ischemic conditioning of the stomach with two-step transthoracic esophagectomy and gastric pull-up with intrathoracic anastomosis after 3 - 7 days. The tip of the gastric tube (later esophago-gastric anastomosis) was measured with HSI. Analysis software provides a RGB image and 4 false color images representing physiologic parameters of the recorded tissue area intraoperatively. These

parameters contain tissue oxygenation (StO_2), perfusion- (NIR Perfusion Index), organ hemoglobin- (OHI) and tissue water index (TWI).

Results. Intraoperative HSI of the gastric conduit was possible in all patients and did not prolong the regular operative procedure due to its quick applicability. In particular, the tissue oxygenation of the gastric conduit was significantly higher in patients who underwent ischemic conditioning ($\overline{\text{StO}_2}_{\text{Precond.}} = 78\%$; $\overline{\text{StO}_2}_{\text{NoPrecond.}} = 66\%$; $p = 0.03$).

Conclusions. HSI is suitable for contact-free, non-invasive and intraoperative evaluation of physiological tissue parameters within gastric conduits. Therefore HSI is a valuable method for evaluating ischemic conditioning effects and may contribute to reduce anastomotic complications. Additional studies are needed to establish normal values and thresholds of the presented parameters for the gastric conduit anastomotic site.

Keywords

Hyperspectral imaging – gastric conduit – esophagectomy – ischemic conditioning – physiologic tissue parameters

Introduction

Esophago-gastric anastomosis following esophageal resection and gastric pull-up is one of the most complex anastomoses of the gastrointestinal tract with a high potential of insufficiency and consecutive complications, as mediastinitis, pleural empyema, esophago-tracheal (-bronchial) fistula and septic erosion bleeding (1). This high risk procedure of esophagectomy has been reported in the literature to be associated with a significant morbidity (>40%) and mortality (5-12%) (2,3). During the process of gastric tube formation in the context of esophagectomy, the major blood vessels of the stomach, such as the left gastric artery and vein, the left gastroepiploic artery and vein, as well as the short gastric vessels are divided, with immediate ischemic reaction of the stomach wall. Viability of the gastric conduit then, however, is mostly dependent on the right gastroepiploic arcade. It has been well analyzed by optical fiber spectroscopy (OFS) that oxygen saturation (SaO_2) and blood flow are significantly reduced during this stepwise devascularization of the stomach and that the extent of resulting gastric tube ischemia is associated with clinical outcomes, e.g. anastomotic leaks (4). The stimulus by relative ischemia following division of major vessels, thus, leads to microvascular improvement by neovascularization (5),

1 especially in the later area of the anastomotic site at the tip of the gastric conduit. The
2 concept of preconditioning, including a two-time procedure with an interval of several
3 days to 2-3 weeks between vessel ligation, gastrolisis and gastric tube transposition
4 into the thorax with anastomosis, is well known as ischemic conditioning (delay
5 phenomenon) of the stomach. This method was first described by Urschel in a rat
6 model (6) and further clinically elaborated and laparoscopically applied by Nguyen et
7 al. in a small series of n=9 patients (7), and in the first large retrospective cohort
8 (n=83 patients) by Hölscher et al. (8) and later comparatively by Schröder et al.
9 (n=419; 238 with ischemic conditioning) of the same clinic (9). During the time period
10 between the first and second intervention and the subsequent delayed transposition
11 and esophagogastric anastomosis, the gastric fundus has time to re-establish an
12 abundant blood supply (10). In general, this partial gastric devascularization can
13 technically be performed by open, laparoscopic or robotic surgery. In addition,
14 preoperative radiologic-interventional arterial embolization has been shown to be
15 equally successful (11–16).

16
17 Although previous methods used for measuring the effects have shown several
18 limitations and are rather time-consuming, the results of this preconditioning concept
19 have been convincing ever since, demonstrating reduction of anastomotic
20 complications following esophagectomy and gastric pull-up in patients and animal
21 models, due to improved perfusion as well as reduced inflammation and fibrosis at
22 the anastomotic site of the gastric sleeve (8,9,17,18). These parameters are known
23 to be the most important factors for regular healing, apart from tension-free and
24 technically perfect performance of the anastomosis. Animal studies have provided
25 evidence that perfusion was 3 times better at re-intervention after ischemic
26 conditioning, going along with increased vasodilation and angiogenesis, less
27 anastomotic collagen deposition, less ischemic injury, and less muscularis atrophy
28 (19). In clinical studies, especially the severity of anastomotic leakage could be
29 reduced significantly (9,20–22). However, a prospective randomized trial (LOGIC trial
30 = laparoscopic gastric ischemic conditioning prior to minimally invasive
31 esophagectomy) by Veeramootoo et al. failed to show improvement of perfusion at
32 the conduit tip (2). In this study, perfusion of the fundus and the greater curvature of
33 the stomach was recorded by laser Doppler fluximetry, which was validated to assess
34 gastric perfusion by others (23,24). A perfusion coefficient measured as ratio at stage

of MIE (minimally invasive esophagectomy) over baseline was used for statistical analysis (2). Others, as the group of Hölscher and Schröder, performed mucosal oxygen saturation (MOS, sulfur dioxide in %) measurements quantitatively from the endoluminal side in well-defined areas of the antrum, corpus and fundus, using a tissue spectrometer located at the tip of a microprobe (8,9,25). In an attempt to search for further reliable methods to assess gastric conduit perfusion, Pham et al. applied optical fiber spectroscopy (OFS) to measure oxygen saturation (SaO₂) and blood volume fraction (BVF) in the distal gastric conduit at baseline and after gastric devascularization, conduit formation, and transposition, with correlation of these readings with clinical outcomes (4). Functional capillary density in ischemic conditioning was assessed by Mittermair et al. in rats in order to investigate time dependent changes of gastric microcirculation by means of intravital fluorescence microscopy (26). Recently, indocyanine green (ICG) fluorescence has been described for evaluating blood supply of the reconstructed tube during esophagectomy (27–29). However, apart from the fact that ICG is an invasive procedure with a considerable rate of cardiovascular complications, comparative studies, regarding the value of ICG in ischemic conditioning of the gastric conduit, are still lacking.

The aim of this study was to evaluate the feasibility of hyperspectral imaging (HSI) for the measurement of ischemic conditioning effects during esophagectomy.

Patients and methods

Only patients who underwent hybrid (abdominal part: minimally-invasive; thoracic part: mini-thoracotomy) or open esophagectomy (n=1 with simultaneous liver resection, see below) could be included, because the used HSI-camera is too large for laparoscopic surgery. Intraoperative hyperspectral images of the gastric tube through the mini-thoracotomy were recorded from n=22 patients (20 males, 2 female) with a median age of 64 (36 - 82) years. Involved were 12 adeno-, 9 squamous-cell carcinomas of the esophagus and 1 reconstruction with gastric pull-up after esophagectomy due to perforation (no carcinoma of the esophagus). In the group of patients undergoing ischemic preconditioning, laparoscopic gastrolisis and ischemic conditioning of the stomach was performed 3-7 days before the operation in n=14 of the 22 patients. In detail, during laparoscopic gastrolisis, first, the lesser omentum

close to the lower edge of the liver, then the greater omentum (including the left gastroepiploic artery and vein) is divided, preserving the gastroepiploic arcade. The left gastric artery and vein are clipped and cut centrally, harvesting the lymph nodes of the celiac trunc, and finally, the short gastric vessels are divided up to the left crus. If possible, the right gastric artery and vein are preserved. Kocher's maneuver of the duodenum is carried out and the distal esophagus with the periesophageal lymph nodes is mobilized intrathoracically as far as possible. Patients were sent to the peripheral ward afterwards and could eat a soft diet. The second step of the operation after ischemic conditioning of the stomach consisted of transthoracic esophagectomy via a mini-thoracotomy (in the sense of a hybrid-procedure) with completion of the two-field lymphadenectomy, gastric tube formation by resection of the lesser curvature and adjacent nodes with a linear stapler (from proximal to distal), and intrathoracic end-to-side esophagogastric anastomosis (circular stapler, EEA 25 mm) at the level of the azygos vein.

The decision on whether to perform ischemic conditioning or not was due to the time interval of surgery: After January 1st 2018, we completely changed our concept towards two-step esophagectomies with ischemic gastric preconditioning in general. Conclusively, patients measured before this point in 2017 underwent the single-step esophagectomy without preconditioning. In one patient, simultaneous liver metastatectomy was performed (segment IV) during open gastrolisis and ischemic conditioning of the stomach. All patients underwent intrathoracic anastomosis, except for the gastric tube pull-up reconstruction following esophagectomy, where we performed a cervical esophago-gastric anastomosis. Clinical data of patients are summarized in **Table 1**.

Immediately before construction of the esophago-gastric anastomosis (stapled end-to-side, EEA 25 mm circular stapler system) the hyperspectral images were acquired with the TIVITA™ Tissue system (Diaspective Vision GmbH, Am Salzhaff, Germany). This HSI-camera has a push broom scanner providing images with a high spectral resolution (5 nm) in the visible and near infrared range (500-1000 nm). The Number of Effective Pixels is 640 × 480 (x-, y-axis). All measurements were taken at a distance of 30 cm between the object and the camera lens with a focal length of 25 mm. This setup results in a field of view (FOV) of 6.4 × 4.8 cm² and a spatial resolution of 0.1 mm/pixel. Illumination is done by 8 halogen spots (20 W each) which are directly integrated in the camera housing. For accurate measurements, the

1 ceiling lights in the operating room were switched off during image recording
2 (approximately 10 seconds). After a computation time of 8 seconds, the analysis
3 software provides a RGB image and 4 false color images that represent physiologic
4 parameters of the recorded tissue area intraoperatively. These parameters contain
5 tissue oxygenation (StO_2), perfusion- (NIR Perfusion Index), organ hemoglobin-
6 (OHI) and tissue water index (TWI). The relative blood oxygenation in the
7 microcirculation of superficial tissue layers (approximately 1 mm) is represented by
8 StO_2 [%], while the NIR Perfusion Index [0-100] represents tissue layers in 4-6 mm
9 penetration depth. The indices OHI [0-100] and TWI [0-100] display the distribution of
10 hemoglobin and water in the observed tissue area, respectively. A detailed
11 description and validation of the parameters can be found in the work of Holmer et
12 al.(30).

13 The location of the later anastomosis was depicted by a forceps during the
14 measurement **Fig. 1**. The area within the diameter of 25 mm around the marked
15 position is called region of interest (ROI). For each parameter image the index
16 average was calculated from the values inside the ROI.

17 Data were collected prospective and analyzed retrospective with LabVIEW. Statistics
18 of physiological parameter indices are presented in mean, median, quartiles and p-
19 value. The f-test was performed to check for equal variances and unpaired two-tailed
20 Student's t-test was used to determine statistical significance. The statistical analyses
21 were performed with Microsoft Excel 2013.

22 Results

23 Intraoperative hyperspectral imaging of the tip of the gastric tube (later anastomosis)
24 was possible through mini-thoracotomy in all our patients undergoing hybrid or open
25 (n=1 patient with simultaneous liver resection during gastrolisis) esophagectomy.
26 HSI measurements did not prolong the regular operative procedure due to its quick
27 applicability (10 seconds per recording and its almost “real-time” possibility of
28 visualization and interpretation). In particular, HSI enabled to distinguish between
29 gastric sleeves with and without ischemic conditioning: A significantly lower mean
30 oxygenation inside the ROI of the gastric conduit was observed in patients without
31 pretreatment (one-step esophagectomy) ($\overline{StO_2}_{NoPrecond.} = 66\%$) compared to patients
32 with ischemic preconditioning ($\overline{StO_2}_{Precond.} = 78\%$; $p = 0.03$). Even though not
33 significant, differences in organ hemoglobin index ($\overline{OHI}_{NoPrecond.} = 42$; $\overline{OHI}_{Precond.} = 46$;
34

p = 0.51) and tissue water index ($\overline{\text{TWI}}_{\text{NoPrecond.}} = 59$; $\overline{\text{TWI}}_{\text{Precond.}} = 63$; p = 0.50) were found for both patient groups. Median, lower and upper quartiles of the ROI mean index for each parameter are summarized in **Table 2** and the distribution among the patients is described in **Fig. 2**.

The postoperative course was uneventful in all patients with regular healing and timely oral nutrition following surgery, except for one non-preconditioned patient. This patient developed a small anastomotic leak of the intrathoracic anastomosis without mediastinitis or sepsis on postoperative day 7, which could be managed conservatively using endoscopic vacuum therapy (Endosponge).

Discussion

Our data clearly show for the first time the feasibility and reliability of hyperspectral imaging (HSI) measuring the ischemic conditioning effects of the gastric conduit and the discrimination possibility to non-preconditioning during esophagectomy. Previous methods used for this analysis in patients and animal models have shown several limitations of application and usefulness and are time-consuming.

The studies supporting the concept of ischemic conditioning, including an animal experiment (8,9,17,18), are of non-randomized character. However, the only prospective-randomized trial (LOGIC trial) (2), did not confirm the benefits claimed for ischemic conditioning. This study might have been underpowered and the final endpoint, anastomotic insufficiency, is known to be multifactorial, strongly depending on the surgeon's technique. A more sophisticated endpoint would have been vascularization of the tip of the gastric tube.

HSI is a relatively new method used in image-guided and precision surgery, which has shown promising results for recognition/characterization of tissues/tumors (31–36), and comprehensive assessment of physiologic tissue parameters, such as perfusion, oxygenation, and water content (37–40). Hence, it has been applied predominantly in wound imaging and -management in plastic surgery transplants, vascular surgery, chronic wounds and burn injuries so far (41–44). In our study group, we were able for the first time to use the system to assess tissue parameters of gastrointestinal anastomoses in visceral surgery *in vivo* (40). HSI, as a contact-free, non-invasive method with no need of contrast medium, provides objective “real time” perfusion-, oxygenation and hydration evaluation of organs and especially of anastomotic sites intraoperatively, which can possibly contribute to determining the

1 “ideal” region of anastomosis with the intent of improved healing (40). HSI-
2 measurements of the gastric conduit during esophagectomy, especially in the context
3 of ischemic conditioning, have not been published so far to our knowledge.

4 The applied HSI-technology in our current study has a relevant advantage over
5 conventional multispectral camera systems due to its higher spectral and spatial
6 resolution. Furthermore, our HSI-camera provides a higher penetration depth
7 compared to the technology of digital cameras (0-1 mm). Thus, deeper tissue layers
8 can be reached by the HSI-camera.

9 Optical fiber spectroscopy (OFS) can be used for the assessment of tissue
10 oxygenation during laparoscopic procedures (4,25). However, OFS covers only a
11 small spot (3 mm) and therefore multiple measurement points are needed, which
12 increases the measuring time. The HSI-camera used in this study is able to cover a
13 large FOV ($6.4 \times 4.8 \text{ cm}^2$) and a wavelength range up to 1000 nm, which enables the
14 additional analysis of tissue water at 960 nm. Other groups determined changes in
15 gastric blood flow with laser Doppler flowmetry, but did not find significant differences
16 between patients with and without ischemic conditioning (2,45). Blood flow cannot be
17 estimated with HSI, but therefore other perfusion-related parameters, like
18 oxygenation and hemoglobin distribution, which seem to be more promising for the
19 analysis of ischemic conditioning effects.

20 In contrast to the increasingly applied technology of Near-InfraRed (NIR)-
21 fluorescence with ICG, which has especially been used in colorectal surgery to
22 reduce anastomotic complications, as impressively shown by the PILLAR II
23 multicenter study (46), the non-invasiveness of our HSI-technology has to be pointed
24 out. Serious and life-threatening side-effects after intravenous application of ICG,
25 such as anaphylactic shock, drop in blood pressure, tachycardia, dyspnea, and
26 urticaria, have been described and the risk of significant adverse and secondary
27 effects rises in patients with chronic renal failure, up to sudden deaths in very rarely
28 reported cases. A further disadvantage of ICG is the subjective evaluation of the
29 fluorescence-intensity by pure envisioning of the surgeon and, thus, reflects its
30 limitations. A new method, called fluorescence-based enhanced reality (FLER), which
31 uses fluorescence time-to-peak was described by Diana et al. (47–49) and showed
32 promising results regarding quantitative ICG-measurement of bowel perfusion in the
33 animal model.

1 In addition, providing comprehensive tissue parameters, such as tissue oxygenation
2 (StO₂), perfusion- (NIR Perfusion Index), organ hemoglobin- (OHI) and tissue water
3 index (TWI), it might be a valuable tool to select the “ideal” anastomotic site of the
4 esophagogastric anastomosis, in order to reduce the risk of leakage. This could be
5 carefully concluded, although casuistic only, by one case of our series, who
6 developed anastomotic insufficiency of the intrathoracic esophago-gastric
7 anastomosis. In this patient, the intraoperative measurements were relevantly lower
8 than the others: StO₂ = 41% (Diff. to $\overline{\text{StO}_2}_{\text{NoPrecond.}}$ = 25%), NIR Perfusion Index = 40
9 (Diff. to $\overline{\text{NIR}}_{\text{NoPrecond.}}$ = 22), OHI = 25 (Diff. to $\overline{\text{OHI}}_{\text{NoPrecond.}}$ = 17). In **Fig. 3** the NIR
10 Perfusion Index image of this patient is compared to a case without postoperative
11 anastomotic leak.

12 The intraoperative measurements are less time-consuming than most other
13 technologies used for assessment of ischemic conditioning effects (about 18 seconds
14 per document), non-invasive, and contact-free. Additionally, they can be technically
15 very easily performed (e.g. by an OR nurse). However, normal and “cut-off” values
16 for gastrointestinal (tubular) organs, especially for different anastomoses, or the
17 “optimal” gastric conduit status (with and without ischemic conditioning), are still to be
18 defined and established, as the technology mainly derives from wound imaging and
19 management. In the latter, e.g. in plastic and vascular surgery, oxygenation of > 50%
20 predicts a good healing of a wound, whereas 30-50% represent a “grey area”, and
21 values of < 30% are associated with worse healing processes in transplants and
22 chronic wounds (50,51). After establishing and generation of normal values and
23 borderline zones of the gastric conduit anastomotic site, the method will be very
24 helpful to determine the best area of perfusion with the optimal constellation of
25 additional parameters, such as oxygenation and edema, in order to avoid
26 postoperative leakages. With regard to the TWI, we found higher values in the group
27 undergoing ischemic preconditioning. This might be due to the fact that patients
28 received additional fluid therapy following laparoscopic gastrotomy and partial
29 devascularization, as some of them displayed signs of minor gastroparesis after this
30 first step of surgery and enteral nutrition was slightly restricted to prevent aspiration
31 events.

32 The used HSI-system is intended for use in plastic surgery and wound diagnostics.
33 For applications in visceral surgery, according to the manufacturer’s website, some
34 improvements are currently under development or planned for the future. This

1 includes focused illumination with LEDs to light up structures deep in the situs and
2 correct for ambient light during open surgery. This also holds for the automatic
3 estimation of the object distance to get a focused image. A major advance will be a
4 compact HSI-camera, which is suitable for laparoscopic procedures and provides
5 high resolution videos.

6 The encountered limitations of HSI for measuring the ischemic conditioning effects of
7 the gastric conduit are the missing gold standard for estimating tissue oxygenation,
8 which makes it difficult to compare it with other methods. The time currently needed
9 for hyperspectral data acquisition and parameter calculation is short (18 seconds) but
10 still not yet fully “real time”, a minor downside compared to ICG-imaging, which shall
11 be improved in the near future.

12 13 **Conclusions**

14 Intraoperative HSI during mini-thoracotomy was used for the evaluation of ischemic
15 conditioning effects. Mean tissue oxygenation and hemoglobin related indices at the
16 later anastomosis location were higher in patients with ischemic preconditioning than
17 without. One patient with noticeable lower values developed anastomotic
18 insufficiency. This work demonstrates, that HSI is suitable for contact-free, non-
19 invasive and rapid intraoperative evaluation of physiological tissue parameters within
20 gastric conduits. Therefore HSI is a valuable method for evaluating ischemic
21 conditioning effects and may contribute to reduce anastomotic complications.

22 23 **Disclosures**

24 *Conflicts of Interest:* The hyperspectral camera used for the measurements in this
25 publication was developed by Diaspective Vision GmbH. H. Köhler is employee of
26 this company. In the long term, Diaspective Vision has proprietary interest in the
27 development of the camera system resulting in a product for routine clinical use. The
28 clinical tests of the camera have been performed by clinicians (authors 2, 4-8 and
29 11). B. Jansen-Winkel, M. Maktabi, M. Barberio, J. Takoh, N. Holfert, Y. Moulla, S.
30 Niebisch, M. Diana, T. Neumuth, S. M. Rabe, C. Chalopin, A. Melzer and I. Gockel
31 have no financial interests and financial arrangements with Diaspective Vision and
32 have received no funding for the measurements and/or preparation of this
33 manuscript. The cameras used during the measurements have been provided by
34 Diaspective Vision.

Funding: Authors state no funding involved.

Ethical approval: Experimental hyperspectral measurements from patients for the evaluation of the new technology have obtained the ethics approval by the Ethics committee of the University Leipzig under 026/18-ek. The study was conducted according to the Declaration of Helsinki.

References

1. Bartels H, Siewert JR. Therapie der Mediastinitis am Beispiel des Ösophaguskarzinoms. Chir. 2008 Jan 1;79(1):30–7.
2. Veeramootoo D, Shore AC, Wajed SA. Randomized controlled trial of laparoscopic gastric ischemic conditioning prior to minimally invasive esophagectomy, the LOGIC trial. Surg Endosc. 2012 Jul;26(7):1822–9.
3. Gockel I, Niebisch S, Ahlbrand CJ, Hoffmann C, Möhler M, Düber C, et al. Risk and Complication Management in Esophageal Cancer Surgery: A Review of the Literature. Thorac Cardiovasc Surg. 2016 Oct;64(7):596–605.
4. Pham TH, Perry KA, Enestvedt CK, Gareau D, Dolan JP, Sheppard BC, et al. Decreased Conduit Perfusion Measured by Spectroscopy Is Associated With Anastomotic Complications. Ann Thorac Surg. 2011 Feb;91(2):380–5.
5. Markar SR, Arya S, Karthikesalingam A, Hanna GB. Technical Factors that Affect Anastomotic Integrity Following Esophagectomy: Systematic Review and Meta-analysis. Ann Surg Oncol. 2013 Dec 1;20(13):4274–81.
6. Urschel JD. Ischemic conditioning of the rat stomach: implications for esophageal replacement with stomach. J Cardiovasc Surg (Torino). 1995 Apr;36(2):191–3.
7. Nguyen NT, Longoria M, Sabio A, Chalifoux S, Lee J, Chang K, et al. Preoperative laparoscopic ligation of the left gastric vessels in preparation for esophagectomy. Ann Thorac Surg. 2006 Jun;81(6):2318–20.
8. Hölscher AH, Schneider PM, Gutschow C, Schröder W. Laparoscopic ischemic conditioning of the stomach for esophageal replacement. Ann Surg. 2007 Feb;245(2):241–6.
9. Schröder W, Hölscher AH, Bludau M, Vallböhmer D, Bollschweiler E, Gutschow C. Ivor-Lewis esophagectomy with and without laparoscopic conditioning of the gastric conduit. World J Surg. 2010 Apr;34(4):738–43.
10. Urschel JD. Ischemic conditioning of the stomach may reduce the incidence of esophagogastric anastomotic leaks complicating esophagectomy: a hypothesis. Dis Esophagus. 1997 Jul 1;10(3):217–9.
11. Akiyama S, Ito S, Sekiguchi H, Fujiwara M, Sakamoto J, Kondo K, et al. Preoperative embolization of gastric arteries for esophageal cancer. Surgery. 1996 Sep;120(3):542–6.

12. Akiyama S, Kodera Y, Sekiguchi H, Kasai Y, Kondo K, Ito K, et al. Preoperative embolization therapy for esophageal operation. *J Surg Oncol*. 1998 Dec;69(4):219–23.
13. Isomura T, Itoh S, Endo T, Akiyama S, Maruyama K, Ishiguchi T, et al. Efficacy of gastric blood supply redistribution by transarterial embolization: preoperative procedure to prevent postoperative anastomotic leaks following esophagoplasty for esophageal carcinoma. *Cardiovasc Intervent Radiol*. 1999 Apr;22(2):119–23.
14. Diana M, Hübner M, Vuilleumier H, Bize P, Denys A, Demartines N, et al. Redistribution of gastric blood flow by embolization of gastric arteries before esophagectomy. *Ann Thorac Surg*. 2011 May;91(5):1546–51.
15. Farran L, Miro M, Alba E, Bettonica C, Aranda H, Galan M, et al. Preoperative gastric conditioning in cervical gastropasty. *Dis Esophagus Off J Int Soc Dis Esophagus*. 2011 May;24(4):205–10.
16. Ghelfi J, Brichon P-Y, Frandon J, Boussat B, Bricault I, Ferretti G, et al. Ischemic Gastric Conditioning by Preoperative Arterial Embolization Before Oncologic Esophagectomy: A Single-Center Experience. *Cardiovasc Intervent Radiol*. 2017 May;40(5):712–20.
17. Nguyen NT, Nguyen X-MT, Reavis KM, Elliott C, Masoomi H, Stamos MJ. Minimally invasive esophagectomy with and without gastric ischemic conditioning. *Surg Endosc*. 2012 Jun;26(6):1637–41.
18. Perry KA, Banarjee A, Liu J, Shah N, Wendling MR, Melvin WS. Gastric ischemic conditioning increases neovascularization and reduces inflammation and fibrosis during gastroesophageal anastomotic healing. *Surg Endosc*. 2013 Mar;27(3):753–60.
19. Reavis KM, Chang EY, Hunter JG, Jobe BA. Utilization of the delay phenomenon improves blood flow and reduces collagen deposition in esophagogastric anastomoses. *Ann Surg*. 2005 May;241(5):736–45; discussion 745–747.
20. Berrisford RG, Veeramootoo D, Parameswaran R, Krishnadas R, Wajed SA. Laparoscopic ischaemic conditioning of the stomach may reduce gastric-conduit morbidity following total minimally invasive oesophagectomy. *Eur J Cardio-Thorac Surg Off J Eur Assoc Cardio-Thorac Surg*. 2009 Nov;36(5):888–93; discussion 893.
21. Veeramootoo D, Shore AC, Shields B, Krishnadas R, Cooper M, Berrisford RG, et al. Ischemic conditioning shows a time-dependant influence on the fate of the gastric conduit after minimally invasive esophagectomy. *Surg Endosc*. 2010 May;24(5):1126–31.
22. Wajed SA, Veeramootoo D, Shore AC. Surgical optimisation of the gastric conduit for minimally invasive oesophagectomy. *Surg Endosc*. 2012 Jan;26(1):271–6.
23. Pierie JP, De Graaf PW, Poen H, Van der Tweel I, Obertop H. Impaired healing of cervical oesophagogastrostomies can be predicted by estimation of gastric serosal blood perfusion by laser Doppler flowmetry. *Eur J Surg Acta Chir*. 1994 Nov;160(11):599–603.
24. Monnet E, Pelsue D, Macphail C. Evaluation of Laser Doppler Flowmetry for Measurement of Capillary Blood Flow in the Stomach Wall of Dogs During Gastric Dilatation-Volvulus. *Vet Surg*. 2006;35(2):198–205.
25. Bludau M, Hölscher AH, Vallböhmer D, Gutschow C, Schröder W. Ischemic conditioning of the gastric conduit prior to esophagectomy improves mucosal oxygen saturation. *Ann Thorac Surg*. 2010 Oct;90(4):1121–6.

26. Mittermair C, Klaus A, Scheidl S, Maglione M, Hermann M, Margreiter R, et al. Functional capillary density in ischemic conditioning: implications for esophageal resection with the gastric conduit. *Am J Surg.* 2008 Jul;196(1):88–92.
27. Ishiguro T, Kumagai Y, Ono T, Imaizumi H, Honjo H, Suzuki O, et al. Usefulness of indocyanine green angiography for evaluation of blood supply in a reconstructed gastric tube during esophagectomy. *Int Surg.* 2012 Dec;97(4):340–4.
28. Kumagai Y, Ishiguro T, Haga N, Kuwabara K, Kawano T, Ishida H. Hemodynamics of the reconstructed gastric tube during esophagectomy: assessment of outcomes with indocyanine green fluorescence. *World J Surg.* 2014 Jan;38(1):138–43.
29. Kitagawa H, Namikawa T, Iwabu J, Fujisawa K, Uemura S, Tsuda S, et al. Assessment of the blood supply using the indocyanine green fluorescence method and postoperative endoscopic evaluation of anastomosis of the gastric tube during esophagectomy. *Surg Endosc.* 2018 Apr;32(4):1749–54.
30. Holmer A, Marotz J, Wahl P, Dau M, Kämmerer PW. Hyperspectral imaging in perfusion and wound diagnostics – methods and algorithms for the determination of tissue parameters. *Biomed Eng Biomed Tech.* 2018 Oct 25;63(5):547–56.
31. Panasyuk SV, Yang S, Faller DV, Ngo D, Lew RA, Freeman JE, et al. Medical hyperspectral imaging to facilitate residual tumor identification during surgery. *Cancer Biol Ther.* 2007 Mar;6(3):439–46.
32. Akbari H, Uto K, Kosugi Y, Kojima K, Tanaka N. Cancer detection using infrared hyperspectral imaging. *Cancer Sci.* 2011 Apr;102(4):852–7.
33. Kumashiro R, Konishi K, Chiba T, Akahoshi T, Nakamura S, Murata M, et al. Integrated Endoscopic System Based on Optical Imaging and Hyperspectral Data Analysis for Colorectal Cancer Detection. *ANTICANCER Res.* 2016;8.
34. Lu G, Little JV, Wang X, Zhang H, Patel MR, Griffith CC, et al. Detection of Head and Neck Cancer in Surgical Specimens Using Quantitative Hyperspectral Imaging. *Clin Cancer Res.* 2017 Sep 15;23(18):5426–36.
35. Beaulieu RJ, Goldstein SD, Singh J, Safar B, Banerjee A, Ahuja N. Automated diagnosis of colon cancer using hyperspectral sensing. *Int J Med Robot.* 2018 Jun;14(3):e1897.
36. Ortega S, Fabelo H, Camacho R, de la Luz Plaza M, Callicó GM, Sarmiento R. Detecting brain tumor in pathological slides using hyperspectral imaging. *Biomed Opt Express.* 2018 Feb 1;9(2):818.
37. Holmer A, Tetschke F, Marotz J, Malberg H, Markgraf W, Thiele C, et al. Oxygenation and perfusion monitoring with a hyperspectral camera system for chemical based tissue analysis of skin and organs. *Physiol Meas.* 2016 Nov 1;37(11):2064–78.
38. Daeschlein G, Langner I, Wild T, von Podewils S, Sicher C, Kiefer T, et al. Hyperspectral imaging as a novel diagnostic tool in microcirculation of wounds. Jünger M, Krüger-Genge A, Jung F, editors. *Clin Hemorheol Microcirc.* 2017 Dec 9;67(3–4):467–74.
39. Kulcke A, Holmer A, Wahl P, Siemers F, Wild T, Daeschlein G. A compact hyperspectral camera for measurement of perfusion parameters in medicine. *Biomed Tech (Berl).* 2018 Mar 9;

40. Jansen-Winkel B, Maktabi M, Takoh JP, Rabe SM, Barberio M, Köhler H, et al. Hyperspektral-Imaging bei gastrointestinalen Anastomosen. *Chir.* 2018 Sep;89(9):717–25.
41. Nouvong A, Hoogwerf B, Mohler E, Davis B, Tajaddini A, Medenilla E. Evaluation of diabetic foot ulcer healing with hyperspectral imaging of oxyhemoglobin and deoxyhemoglobin. *Diabetes Care.* 2009 Nov;32(11):2056–61.
42. Jeffcoate WJ, Clark DJ, Savic N, Rodmell PI, Hinchliffe RJ, Musgrove A, et al. Use of HSI to measure oxygen saturation in the lower limb and its correlation with healing of foot ulcers in diabetes. *Diabet Med J Br Diabet Assoc.* 2015 Jun;32(6):798–802.
43. Calin MA, Coman T, Parasca SV, Bercaru N, Savastru R, Manea D. Hyperspectral imaging-based wound analysis using mixture-tuned matched filtering classification method. *J Biomed Opt.* 2015 Apr;20(4):046004.
44. Sakota D, Nagaoka E, Maruyama O. Hyperspectral imaging of vascular anastomosis associated with blood flow and hemoglobin concentration. *Conf Proc Annu Int Conf IEEE Eng Med Biol Soc IEEE Eng Med Biol Soc Annu Conf.* 2015;2015:4246–9.
45. Urschel JD, Antkowiak JG, Delacure MD, Takita H. Ischemic conditioning (delay phenomenon) improves esophagogastric anastomotic wound healing in the rat. *J Surg Oncol.* 1997 Dec;66(4):254–6.
46. Jafari MD, Wexner SD, Martz JE, McLemore EC, Margolin DA, Sherwinter DA, et al. Perfusion Assessment in Laparoscopic Left-Sided/Anterior Resection (PILLAR II): A Multi-Institutional Study. *J Am Coll Surg.* 2015 Jan;220(1):82–92.e1.
47. Diana M, Noll E, Diemunsch P, Dallemagne B, Benahmed MA, Agnus V, et al. Enhanced-Reality Video Fluorescence: A Real-Time Assessment of Intestinal Viability. *Ann Surg.* 2014 Apr;259(4):700–7.
48. Diana M, Halvax P, Dallemagne B, Nagao Y, Diemunsch P, Charles A-L, et al. Real-time navigation by fluorescence-based enhanced reality for precise estimation of future anastomotic site in digestive surgery. *Surg Endosc.* 2014 Nov;28(11):3108–18.
49. Diana M, Agnus V, Halvax P, Liu Y-Y, Dallemagne B, Schlagowski A-I, et al. Intraoperative fluorescence-based enhanced reality laparoscopic real-time imaging to assess bowel perfusion at the anastomotic site in an experimental model: Intraoperative fluorescence-based enhanced reality laparoscopic real-time imaging. *Br J Surg.* 2015 Jan;102(2):e169–76.
50. Keller A. A new diagnostic algorithm for early prediction of vascular compromise in microsurgical flaps using tissue oxygen saturation measurements. *Ann Plast Surg.* 2009 May;62(5):538–43.
51. Jafari-Saraf L, Wilson SE, Gordon IL. Hyperspectral image measurements of skin hemoglobin compared with transcutaneous PO2 measurements. *Ann Vasc Surg.* 2012 May;26(4):537–48.

Table 1 Patient demographics and tumor histology

Variables	Ischemic preconditioning	
	Yes (n=14)	No (n=8)
Median age [range] in years	63 [36 - 77]	68 [52 - 82]
Sex, n (males : females)	13 : 1	7 : 1
Tumor type		
Adenocarcinoma	7	5
Squamous-cell carcinoma	7	2
None	-	1
Tumor localization		
Lower third of the esophagus	8	4
Lower and middle third	-	1
Middle third	5	2
Upper third	1	-
None	-	1
Neoadjuvant therapy		
Chemotherapy	4	4
Chemo radiotherapy	9	2
Radiotherapy	1	-
None	-	2

Table 2 Statistics of ROI mean index of measured gastric tubes for each parameter

Table 1 Statistics of ROI mean index of measured gastric tubes for each parameter

Parameters Median [lower-, upper quartile]	Ischemic preconditioning		P value
	Yes (n=14)	No (n=8)	
Tissue oxygenation (StO ₂)	0.78 [0.71, 0.82]	0.69 [0.55, 0.80]	0.03
NIR Perfusion Index	0.68 [0.61, 0.72]	0.62 [0.59, 0.70]	0.22
Organ hemoglobin index (OHI)	0.52 [0.42, 0.57]	0.43 [0.31, 0.49]	0.51
Tissue water index (TWI)	0.63 [0.53, 0.72]	0.55 [0.51, 0.62]	0.50

Fig. 1 RGB image with marked ROI at later anastomosis location (left) and false color image of tissue oxygenation (right).

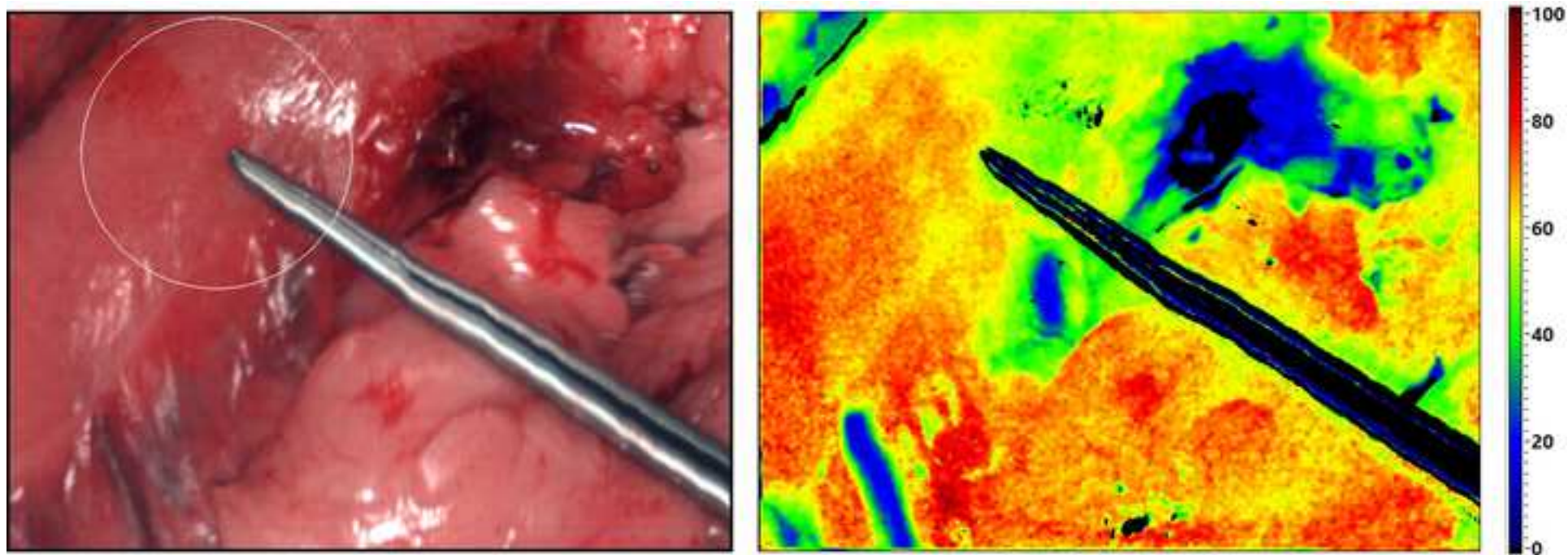


Fig. 3 RGB- and NIR Perfusion Index- images of a patient with (A, B) and without postoperative anastomotic insufficiency (C, D).

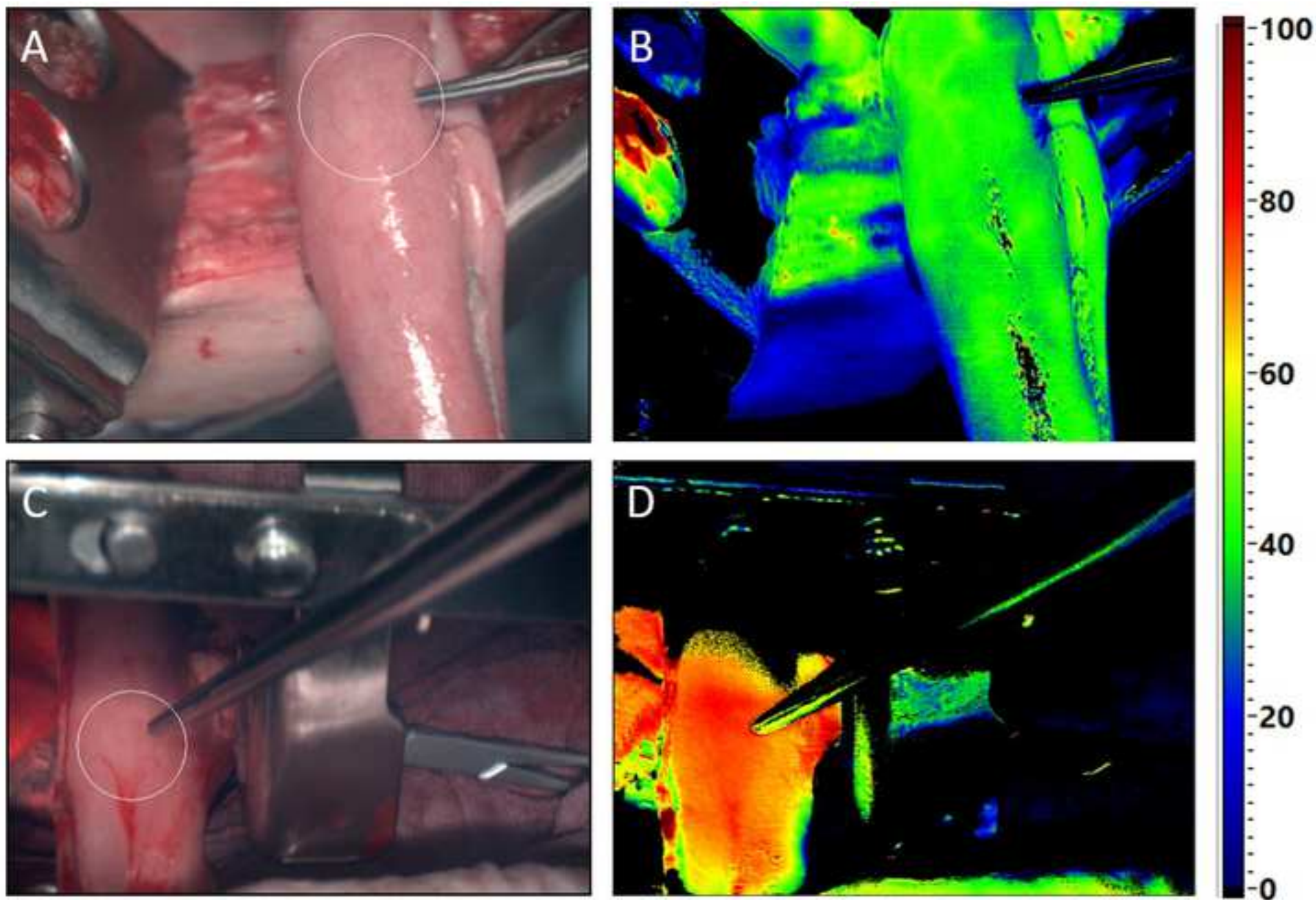


Fig. 2 Distribution of the index average inside the ROI among patients with and without ischemic preconditioning for a) tissue oxygenation (StO₂), b) perfusion- (NIR Perfusion

