

University of Dundee

Different methods of canine retraction-Part 2

Nahidh, Mohammed; Yassir, Yassir A.; McIntyre, Grant T.

DOI:
[10.26477/jbcd.v35i1.3314](https://doi.org/10.26477/jbcd.v35i1.3314)

Publication date:
2023

Licence:
CC BY

Document Version
Publisher's PDF, also known as Version of record

[Link to publication in Discovery Research Portal](#)

Citation for published version (APA):
Nahidh, M., Yassir, Y. A., & McIntyre, G. T. (2023). Different methods of canine retraction-Part 2. *Journal of Baghdad College of Dentistry*, 35(1), 58-75. <https://doi.org/10.26477/jbcd.v35i1.3314>

General rights

Copyright and moral rights for the publications made accessible in Discovery Research Portal are retained by the authors and/or other copyright owners and it is a condition of accessing publications that users recognise and abide by the legal requirements associated with these rights.

Take down policy

If you believe that this document breaches copyright please contact us providing details, and we will remove access to the work immediately and investigate your claim.

Different methods of canine retraction- Part 2

Mohammed Nahidh^{1*}, Yassir A. Yassir², Grant T. McIntyre³

¹ Ph.D. student, Department of Orthodontics, College of Dentistry, University of Baghdad, Baghdad, Iraq

² Assistant Professor, Department of Orthodontics, College of Dentistry, University of Baghdad, Baghdad, Iraq. Bab-Almoatham, P.O. Box 1417, Baghdad, Iraq.

³ Honorary Professor of Orthodontics. School of Dentistry, University of Dundee, UK.

* Correspondence email: m_nahidh79@codental.uobaghdad.edu.iq

Received date: 18-02-2022

Accepted date: 01-03-2022

Published date: 15-03-2023



Copyright: © 2022 by the authors. The article is published under the terms and conditions of the Creative Commons Attribution (CC BY) license

<https://creativecommons.org/licenses/by/4.0/>.

<https://doi.org/10.26477/jbcd.v35i1.3314>

Abstract: Background: This review aims to discuss various canine retraction techniques using frictionless mechanics. Methods: Between 1930 and February 2022, searches were conducted about various canine retraction techniques using fixed orthodontic appliances in various databases, including PubMed Central, Science Direct, Wiley Online Library, the Cochrane Library, Textbooks, Google Scholar, Research Gate, and manual searching. Results: After removing the duplicate articles, publications that described how to use archwires to perform canine retraction with the archwires were included. Conclusions: The pros and cons of various canine retraction techniques using archwires were thoroughly discussed. T-loop is the preferred spring of all because of its characteristics.

Keywords: Canine, retraction, fixed appliance, frictionless technique.

Introduction

Separate cuspid retraction is indicated in the cases of anterior teeth crowding, high canines, and midline discrepancy. Alignment using continuous archwire may lead to incisor proclination that may cause labial bone defect, so separate canine retraction with frictionless mechanics is preferred over the continuous archwire technique to lessen these side effects ⁽¹⁾. This review comprehensively describes all developed canine retraction methods using frictionless mechanics.

Canine retraction with the archwire (frictionless technique)

In frictionless mechanics, a canine is moved individually with loops like "a train car being picked up and moved by a crane" ⁽²⁾.

Advantages

1. More esthetic since incisors bonding is often not essential ⁽³⁾.
2. Alignment of incisors can happen rapidly, simultaneous with canine retraction ⁽³⁾.
3. There is no binding and friction, so there is no loss of applied forces ⁽⁴⁾.
4. The retraction mechanics is predictable as the number of forces and moments are quantifiable ⁽¹⁾.
5. Adequate 'rebound time' for uprighting and arch leveling ⁽²⁾.

Disadvantages

1. It requires significant chair-side time ⁽¹⁾.
2. Loops are uncomfortable for the patient and may cause hygiene problems ⁽²⁾.

3. Transverse control of the canines during retraction is reduced compared with sliding mechanics⁽¹⁾.
4. Controlled root movement may not be easily accomplished as the loop incorporates more wire, decreasing the overall flexural rigidity⁽³⁾.
5. Anchorage reinforcement is required⁽³⁾.
6. Non-preferable rotation in the sagittal and transverse plane results from wrong mechanics will increase aligning stage⁽⁴⁾.

Methods of canine retraction with the archwire

Canines are distalized using three primary methods:

- (1) Full archwire without bonding the incisors
- (2) Full archwire with bonding to the incisors
- (3) Sectional arches:
 - a) Bull loop
 - b) Burststone cuspid retraction spring
 - c) Ricketts retraction spring
 - d) Burststone T-loop attraction spring
 - e) Reverse closing loop (helical loop)
 - f) PG retraction spring
 - g) Hybrid retraction spring
 - h) Mushroom loop
 - i) Remaloy cuspid retraction spring
 - j) Nitanal Spring
 - k) Wave spring
 - l) Marcotte spring
 - m) Modified Marcotte spring
 - n) Three-dimensional canine loop
 - o) Simultaneous torquing, aligning, and retraction (S-TAR) spring
 - p) Retraction loop (R-loop)

(1) Full archwire without bonding the incisors

In this method, a continuous archwire with two loops on each side retracts the canines without bonding the incisors⁽⁵⁾.

The anterior loop is pear-shaped, in contact with the mesial surface of the canine brackets, and opened on activation. The posterior (distal) loop is a reverse U-loop (closing loop) located 2 mm behind the canine bracket, activated by closing the loop to approximate the two arms of the loop. The anterior section of the archwire is contoured to come in light contact with the incisors left without brackets.

The activation of this design is performed by pulling the archwire through the molar tube and turning it down (up according to the arch) so as the anterior (mesial loop) will be opened about 1mm and the posterior (distal) loop will be closed by the same amount. In some occasions, light intra- or inter-maxillary elastics may be used to exert a light force of 50-60 grams, hooked to the anterior loop so that it will pull the anterior section of the archwire resulting in compressing the anterior loop; thus, the canine is retracted by the pushing action of the anterior loop and the pulling action of the posterior loop. An archwire of 0.016 and 0.018- inches is supposed to be suitable for tipping the canine distally (Figure 1).

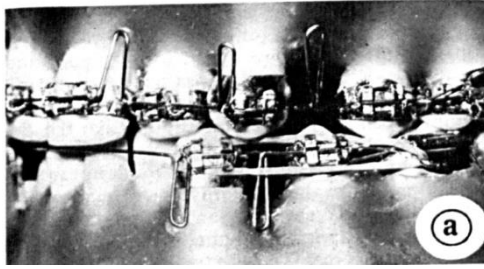


Figure 1: Canine retraction using full archwire without bonding the lower incisors

Advantages

1. Canine control in the transverse plane is best done with a full archwire.
2. The incisors will be aligned spontaneously because they are left without an archwire.

Disadvantages

1. Such a design needs an experienced orthodontist in wire bending as the distance between the canine brackets should be determined accurately to get correctly positioned mesial loops.
2. In some circumstances of over-activation by the loops and elastics, the incisors may be retroclined from the pressure of the archwire.
3. Irritation of the lips may occur as the archwire is not ligated to the incisors' brackets, and to solve this problem, a plastic tube or sleeve is used to protect the lip and the archwire from deformation.
4. A limited number of activations can be performed with this design before the heavy contact of the archwire with the incisors.

(2) Full arch with the bonding of the incisors

In this technique, the incisors will be bonded either for anchorage purposes or for aligning purposes⁽⁵⁾:

(a) Incisors bonded for anchorage

Here, the same design of wire bending discussed in the previous section is used except for including the incisors by bending the archwires to lie passively in their brackets. This technique is not indicated in severely crowded or imbricated incisors because ligating them with an archwire is challenging.

Advantage

1. More comfortable for the patient as there is no chance of distortion for the anterior section of the archwire or trauma.

Disadvantages

1. Some forward movement of the anterior teeth is anticipated when activating this design, although the distal movement of the canines will counteract it.
2. Incisor alignment may not occur spontaneously as in the previous method.

(b) Incisors bonded to permit their alignment during canine retraction

A flexible round archwire of 0.014, 0.016, or 0.020-inch stainless steel is used according to the bracket slot size to bend the vertical multi-looped design between each incisor. Moreover, two vertical loops mesial and 2mm distal to the brackets of the canines, just like the previous design, are bent too. In some cases, the distal loop can be omitted, and the wire left plain distal to the canine brackets, provided that the force exerted by the intra-maxillary elastics attached to the canine brackets will augment the distal movement of the canines. Before ligating the archwire to the anterior teeth, all the anterior loops must be opened in a very small amount, then the arch is tied in, and activation is performed by pulling the ends of the wire through the molar tubes and turning them down (Figure 2).

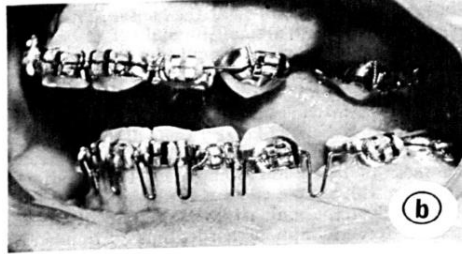

Figure 2: Canine retraction using full archwire with bonding the incisors for their alignment

Advantage

1. Prompt alignment of all the teeth can be attained at the early stages of treatment.

Disadvantages

1. Proclination of the incisors can happen mostly with substantial crowding in the area of incisors, yet the counteraction effect of the intra-maxillary elastics, which results in closing the anterior loops, may retrocline the incisors providing adequate space is available.
2. The method requires more chair time and sound manipulation in wire bending as the inter-bracket distance is short.
3. This design is traumatic to the lips and gingivae.
4. This technique must be used cautiously in severe crowding, or anchorage control is critical.
5. Binding of the archwire may be occurred upon using intra-maxillary traction elastics, preventing the free sliding of the wire through the second premolar brackets and molar tubes, leading to proclination of the whole labial segment.

(3) Sectional arch

A section of the archwire extends from the first molar to the canine bracket without passing the anterior teeth. It consists of a vertical loop located distal to the canine bracket with different designs activated by pulling up the wire through the molar tube and cinching back. It has been shown that the activation of the sectional arch is better done by closing rather than opening the loop because the resistance of the wire to deformation will be increased as the wire is deformed in the original direction of bending.

It can be made from a round flexible or rigid rectangular archwire. The complex design of the sectional arch will include more wire length that makes the loop more flexible and produces constant force over a longer distance. This design is preferred to retract mesially angulated canines by tipping, while a less flexible loop is desirable to retract a distally angulated canine that needs more movement control.

Unlike the sectional arch constructed from rectangular wire, the one constructed from round wire may rotate around the bracket, so a stop must be incorporated mesial to the canine bracket to form two points of contact to prevent that rotation.

The anchorage issue is essential to control by ligating the second premolar with the first molar, using the Nance button, trans-palatal arch, and lingual arch, incorporating tie-back loop or V-bend just distal to the second premolar bracket to permit frequent reactivations. Anti-tip and anti-rotation bends must be incorporated into the sectional arch to prevent the tipping and rotation of the canine during retraction⁽⁵⁾.

Advantages

1. Patients prefer a sectional arch as no wire will cross the incisors (esthetic).
2. Automatic alignment of the anterior teeth (while remaining within the muscle balance zone) can be anticipated in many cases as the canine is retracted in the extraction space.
3. Quick and easy reactivation.
4. A round sectional wire is easy to fabricate.

Disadvantages

1. Trauma to the patient can be caused by the loop being buried in the mucosa or sticking out into the cheek, especially with round sectional wire, as it may rotate in the bracket.
2. The movement of the canine is tricky to control with a round wire.
3. Severe distal tipping may have occurred if the orthodontist inadvertently did not counteract that with proper wire bending or used round sectional wire.
4. If constructed from a round wire, substantial buccal movement of the canines may occur if it does not lie passively in the canine bracket in the buccolingual plane.

Sixteen different types of sectional arches have been used in canine retraction:

(a) Bull loop

This spring was introduced by Dr. Harry Bull and took its name from the founder. It is made of 0.021×0.025 inch stainless steel wire with closed-loop (two closely approximating vertical arms) situated mid-way in the space of extracted first premolar and two legs (mesial and distal). The distal one contains a small tie-back loop forward to the second molar tube (Figure 3). The activation entails bending the mesial leg gingivally about 45°-60° to engage the mesial surface of the canine's bracket and pulling the distal end behind the last molar tube and bending it down so open the closed-loop not more than 1mm, leading to canine retraction bodily^(6,7).

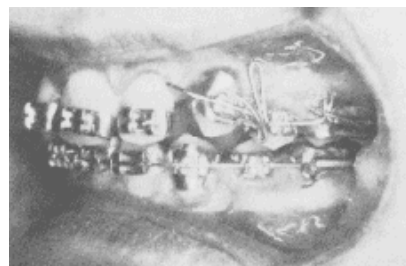


Figure 3: Canine retraction using Bull spring

(b) Burstone Cuspid Retraction Spring

Burstone⁽⁸⁾ developed a cuspid sectional retraction spring by combining heavy and light wires to get maximum control. The distal force delivered to retract the canine was gained from an anterior segment fabricated of a light 0.008×0.020 inch 18-8 stainless steel wire. The other part of the spring, called also the base or depression segment fabricated of 0.015×0.028 inch steel wire (Figure 4). Upon activation, the spring delivered distal force and couples that prevent canine rotation, also maintaining the center of rotation at the apex. The force and moments tend to tip back the posterior segments and elevate them by a gingival bend incorporated within the depression segment.

As usually done in segmented arch mechanics, anchorage must be well prepared using a heavy 0.0215×0.028 inch archwire segment to stabilize the buccal segments and the trans-palatal arch. Using this spring, cuspid retraction was performed within twelve weeks with a maximum force magnitude of approximately 175 gm.

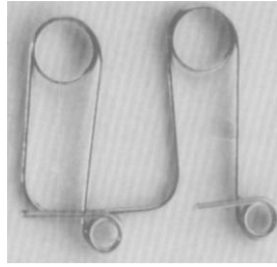


Figure 4: Burstone cuspid retraction spring

(c) Ricketts retraction spring

Ricketts and his associates ⁽⁹⁾ developed two types of retraction springs, one for retracting maxillary canines, called double vertical crossed T closing loop, and the other for the lower canine and called double vertical helical closing loop (Figure 5). They are fabricated from 0.016×0.016 Blue Elgiloy and activated 2-3 mm by pulling the wire behind the first molar tube and cinching back to give about 50 gm for the maxillary spring and 75 gm for the mandibular one. Anchorage is controlled using the Nance appliance in the maxillary and lingual arch or the utility arch in the lower arch. Elastic thread can be used from the lingual side to control the rotation of the canine during retraction.




Figure 5: Ricketts cuspid retraction springs

(d) Burstone T-loop attraction spring

This type of retraction loop was introduced and developed by Dr. Burstone in 1982. It is designed for canine retraction in the segmented arch technique. It is fabricated from 0.017×0.025 inch beta-Titanium archwire.

It consists of a horizontal loop of 10 mm in length and 2 mm high, a mesial leg of 5 mm in height, and a distal leg of 4 mm in height positioned equidistant between the molar band and the bracket of the canine (Figure 6).

T-loop is activated horizontally by 4 mm with six pre-activation points, each of 30°, making a total of 180° activation. In order to prevent the rotational tendency of the canine, anti-rotation bends of 120° are performed in the mesial leg of the loop ⁽¹⁰⁾.

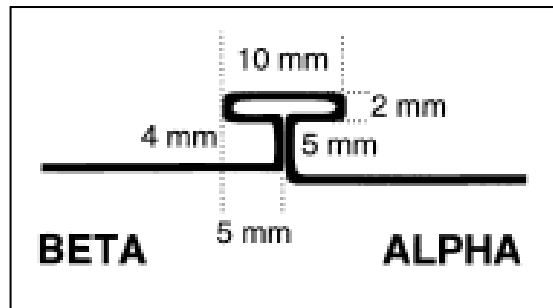


Figure 6: Burstone T-loop spring

Advantages

Unlike the vertical loops, it is designed to make the moment-to-force ratio more constant, which can be achieved by decreasing the load-deflection rate and using the T loop design, which increases the activation moment by placing wire more apically.

Bourauel *et al.* ⁽¹¹⁾ modified the original T-spring of Burstone by developing the superelastic T-loop for a canine or en-masse retraction. It consisted of a NiTi T-segment and stainless steel arms connected via crimpable hooks to the NiTi segment.

(e) Reverse closing loop (closed helical vertical loop)

This loop was developed by Ulgen ⁽¹²⁾ and used by Dinger and Işcan ⁽¹³⁾ to retract the maxillary and mandibular canines. It consists of two vertical arms 2mm apart, a helix (to increase the flexibility of the wire and decrease the force produced), and a tie-back small loop just distal to the second premolar bracket (Figure 7). Activation is performed by tightening a steel ligature wire between the tie-back and the hook of the molar band so that when it is pulled tight, the arms of the loop come in contact.

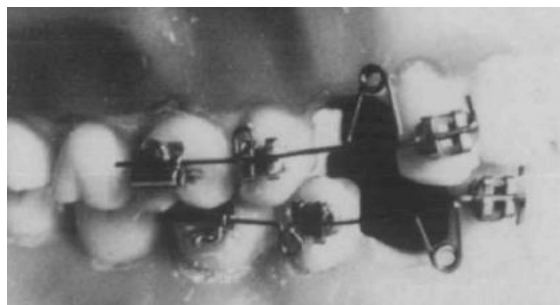

Figure 7: Reverse closing loop

(f) PG retraction spring

Poul Gjessing introduced this type of spring in 1985. It is fabricated from 0.016×0.022-inch stainless steel wire and designed for controlled retraction of canines and maxillary incisors. The main active wire component is the ovoid double helix loop that extends 10 mm apically to decrease the load/deflection of the spring. Moreover, it is placed gingivally so that the activation will cause tipping of the short horizontal arm (attached to the canine) in a direction that will increase the couple acting on the tooth. The other part is a small loop located occlusal to close the loop on activation, while the third part is the mesial and distal extensions of the looped wire segment, which are angulated vertically and horizontally (Figure 8).

The spring activation is performed by pulling the distal leg through the molar tube and turning it so that the two sections of the double helix are separated by 1 mm. This will give approximately 140-160 gm of

force. The activation is repeated every four weeks, and the expected controlled canine movement is approximately 1.5 mm per activation⁽¹⁴⁾.

Advantage

1. It produces more rapid retraction with less tipping of the canines.

Disadvantages

1. It is a bulky spring.
2. The variations in the depth of the buccal sulcus may limit the loop's height.

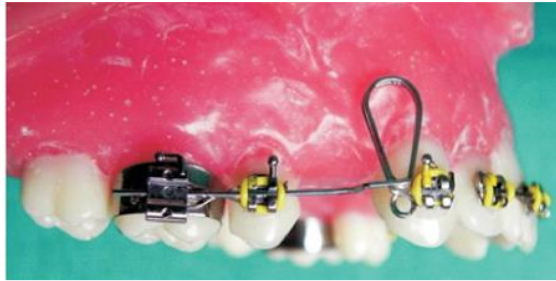

Figure 8: PG retraction spring

(g) Hybrid retraction spring

This type of retraction means called so since various materials are used in construction. It consists of an encapsulated superelastic compression spring (force-producing part), a protective tube of 2.2 mm in diameter, a spacer, a superelastic piece of 0.018×0.018 wire (inserted at an angle in the vertical slot of the canine bracket from one side and the protective tube from the other side) and a piece of 0.017×0.025 inch rectangular stainless steel wire inserted into the auxiliary tube of the molar band (Figure 9).

Before insertion in the slot, the superelastic piece is twisted about 45° to produce the anti-rotational moment. To ensure canine retraction along the alveolar process, a bend with 10 to 15° is introduced, and a further compensatory bend in accordance with the course of the dental arch is added to the steel portion to ensure that the canine is not moved buccally. The activation range of this spring is 5 mm⁽¹⁵⁾.

Advantages

1. In comparison with other springs, actual bodily canine retraction can be performed.
2. The steel portion of the wire allows the introduction of second and third-order bends.
3. It can be used for en-masse retraction of incisors.

Disadvantages

1. A custom bracket with a vertical slot is required.

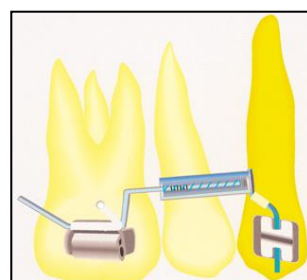

Figure 9: Hybrid retraction spring

(h) Mushroom loop

From its name, it looks like a mushroom and is similar to the T-loop but with a curved apical area. It is used for individual canine retraction and en-masse retraction of all anterior teeth in a continuous archwire incorporating sufficient torque (Figure 11). It can be fabricated from 0.017×0.025 inch beta-Titanium archwire, yet 0.016×0.022 inch may be of choice for adults needing low force to move their teeth ⁽¹⁶⁾.

Advantages

1. Due to the archival configuration in the apical part of that spring, the force produced will be low and continuous while the generated moment will be increased on activation. This will increase the M/F ratio and allow greater root and anchorage control.
2. The force delivery is more constant as the loop is fabricated from a beta-Titanium archwire with a much lower stiffness than stainless steel.

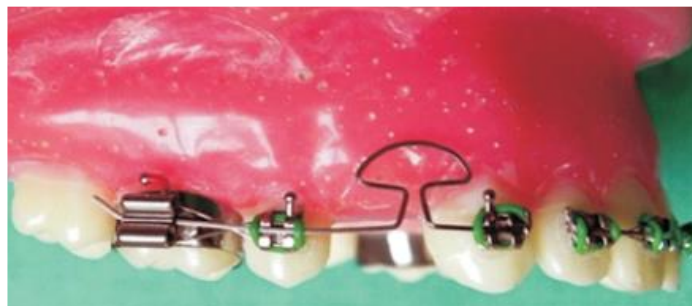

Figure 11: Mushroom loop

(i) Remaloy cuspid retraction spring

It is a type of ready-made sectional archwire for canine retraction developed by Ladanyi ⁽¹⁷⁾ and made from 0.016×0.022 inch Blue Elgiloy wire to modify the closed helical vertical loop. It is activated by introducing anti-tip, and anti-rotation bends, gently pulling distal to the molar tube, and bending down, so the two legs approximate each other (Figure 12).

Advantages

1. It delivers a light force of about 90 gm/mm per activation.
2. It is gentle and long-acting as it contains a loading spring.
3. It can produce canine bodily retraction.

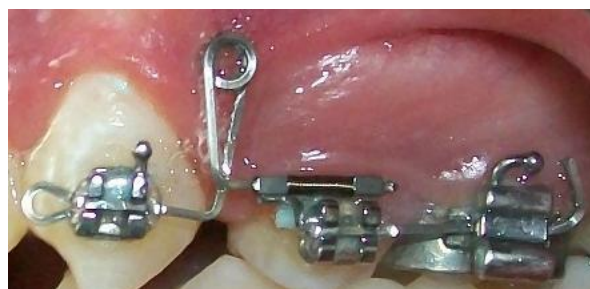

Figure 12: Remaloy cuspid retraction spring

(j) Nitanal Spring

Watanabe and Miyamoto⁽¹⁸⁾ developed a canine retraction spring of 0.016×0.022 inch nickel-titanium wire. It consists of a simple vertical closing loop with anti-tip, and anti-rotation bends placed using three-prong pliers. It is then embedded in a heat-resistant plaster to maintain its shape for 15 minutes at 550°C (Figure 13).

Advantages

1. It can deliver continuous forces and moments over a wide range of activation.
2. It can retract the canines and level the posterior teeth concurrently.
3. It provides a continuous light force.
4. It can be activated as much as 10 mm; hence canine retraction can be achieved with only one activation, decreasing patient discomfort, chair time, and the frequency of appointments.

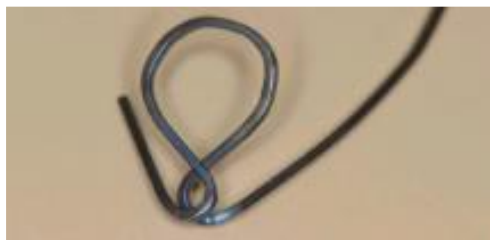

Figure 13: Nitanal Spring

(k) Wave Spring

It looks like a wave when extended (Figure 14). It is fabricated from superelastic nickel-titanium alloy and has a 6mm length in resting state. It can deliver a comparatively large activation force, reaching 90 grams. This spring can return to its original shape without deformation even after activation to more than three times its resting length⁽¹⁸⁾.




Figure 14: Wave spring in resting and activation states

Advantages

1. Unlike the closed coil spring, the spring is stretched linearly during activation, and when it returns to its resting position, it will not produce unwinding torque.
2. It is hygienic and comfortable as it does not contain coils, so it will not protrude into the buccal vestibule.
3. Eyelets are integrated into the original design, eliminating the eyelets from loosening or falling off.
4. The spring can be doubled up without becoming bulky if more force is required.

(l) Marcotte Spring

Michael Marcotte developed this spring in 1990 ⁽²⁰⁾. It is fabricated from 0.016-inch stainless steel wire with a single closing vertical loop of 6 mm length and 2mm width. It extends from the auxiliary tube of the first molar tube to the canine bracket and can be activated by pulling the wire exit through the auxiliary tube and cinched back gingivally.

Advantages

1. The design of the spring is straightforward.
2. It can be fabricated at the chair side.

Disadvantages

1. The wire is small in diameter that is liable to deformation.
2. Trauma to the soft tissue due to impingement may occur.
3. Loss of torque and rotational control, so it is used for minor canine retraction (about 1-2 mm).

(m) Modified Marcotte spring

This spring consists of a 6–8 mm height and 3 mm width closing loop, with the distance between the two arms being about 2 mm (Figure 15). It looks like the original Marcotte spring but fabricated from 0.017 × 0.025 inch TMA archwire to provide a superior fit in the auxiliary molar tube, with an internal dimension of 0.018 × 0.025 inches ⁽²¹⁾. Before activation, just like the Marcotte spring, an anti-rotational bend of about 10°–15° is placed on the mesial arm in addition to a mesial tip of 15°–20°. An anti-extrusion bend of 20°–30° is placed on the distal arm to prevent extrusion.

Advantages

1. The design of the spring is straightforward.
2. It can be fabricated at the chair side.
3. Offers better rotational and directional control.

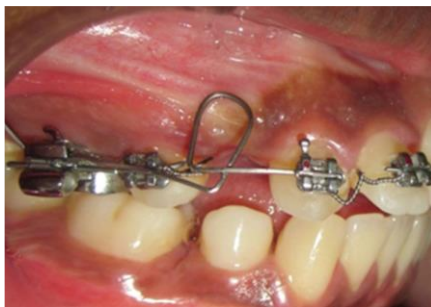

Figure 15: Modified Marcotte spring

(n) Three-dimensional canine loop

Mehrotra *et al.* ⁽²²⁾ developed a three-dimensional loop (3D loop) for treating ectopically erupted canine using sectional TMA 0.017× 0.025 inch archwire. It consists of a closing loop with a 6 mm length mesial vertical arm and a 13 mm in length distal vertical arm with a 2mm distance between them. The distal vertical arm is longer than the mesial one to facilitate canine extrusion and can be adjusted with regard to the need for extrusion by bending it 90° to form the active arm that will engage the slot of the palatally bonded bracket. Usually, this distal vertical arm is bent toward the tissue surface for ease of placement (Figure 16).

Anchorage is maintained using the trans-palatal arch. To activate this loop, the active arm is bent 15° to give palatal root torque to maintain the canine root in the cancellous bone, avoiding the cortical anchorage and the chance of dehiscence throughout the treatment. A mesial up or down 15° bend can be added to the active arm to correct the canine angulation. The distal extension of the mesial arm will be inserted into the auxiliary tube of the molar band.

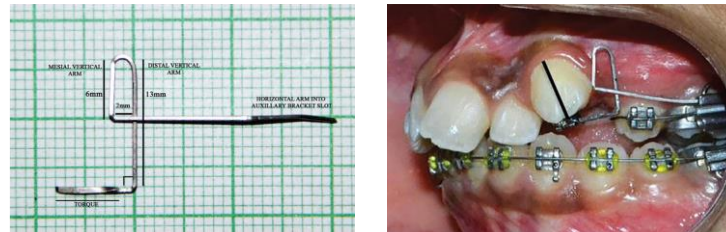


Figure 16: Three-dimensional canine loop

Advantages

1. The canine will be moved in three space planes (tip, torque, and extrusion).
2. The patient feels less discomfort because the attachment will be bonded on the palatal surface of the malposed canine, so the possibility of mucosal ulceration of lips and cheeks will be less.

(o) Simultaneous torquing, aligning, and retraction (S-TAR) spring

Jain *et al.* ⁽²³⁾ developed S-TAR spring to control the torque and extrusion during canine retraction into the extraction space. It extends from the auxiliary tube of the molar band to the canine (Figure 17). It is fabricated from 0.017×0.025 inch TMA archwire. It consists of a closing loop of 9 mm height with a 2mm distance between the legs (to aid in retraction), a V-bend located distal to the canine (to aid in localizing the torque to the anterior segment of the spring), and a box anterior to the V-bend with 3-4mm height (to aid in maintaining the torque and tip during the retraction of the canine). Activation is performed by pulling the wire distal to the molar tube so that the legs of the vertical loops come in contact and then bent back in addition to the pre-activation lingual root torque anterior to the V-bend by about 15°.

Advantages

1. It is easy to fabricate and activate on the chair side.
2. It provides control during canine retraction in all three planes of space.

Disadvantage

1. Soft tissue trauma might occur depending on the height of the buccal vestibule.

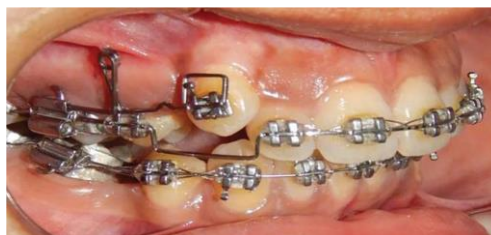

Figure 17: S-TAR spring

(P) Retraction loop (R-loop)

This loop type is fabricated from 0.017×0.025 inch TMA archwire and designed to correct the ectopic labially positioned canine (Figure 18). It extends directly from the molar tube to the canine bracket or may pass through the second premolar bracket ⁽²⁴⁾. The vertical loop can be added to increase the flexibility of the spring.

Advantages

1. It is simple to fabricate and takes less chair time.
2. It prevents the canine's root tip from overriding the incisors.
3. Retracting ectopic canine by this spring will preserve the attached gingiva and the periodontal health of the tooth.

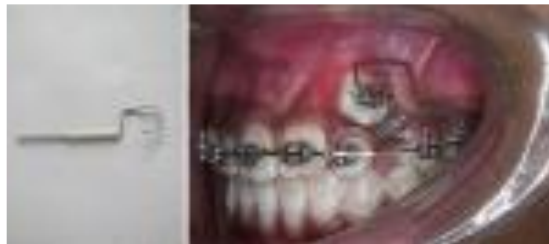

Figure 18: R-loop

Miscellaneous methods of canine retraction

(1) Sectional stainless steel archwire with elastomeric chain

A piece of heavy gauge rectangular archwire extended directly from the canine bracket to the molar tube, engaging these teeth passively and ending with a stop mesial to the canine bracket. A hook (maybe soldered) or crimpable hook may be crimped directly to the archwire about 3 mm distal to the canine bracket to act as a point of force application for attaching an elastomeric chain to retract the canine by sliding ⁽⁵⁾.

Advantages

1. The chance of wire binding is meager as the archwire is extended from the canine bracket to the molar tube, so the sliding will be easy.
2. This technique can be used even if the second premolar is not erupting.
3. More comfortable and esthetic to the patient as fewer teeth are bonded.
4. Quick technique as it does not require extensive wire bending (just the stop) and takes less chair time.

Disadvantages

1. The anchorage issue is the main disadvantage of this method as if the archwire incorporated anchorage bend; it will cause excessive friction in the molar tube, moreover; incorporating the second premolar cannot be done. The Nance button will provide good anchorage in anterior-posterior and transverse dimensions with or without a trans-palatal arch.
2. This technique can be applied only if the canine and molar are upright and aligned in the arch.

(2) Sectional Nickel-Titanium archwire with elastomeric chain

This technique uses a straight section of 0.017×0.025 inch Nitinol archwire with some first-order bends performed using triple-beaked pliers without needing the third-order bends. After three weeks of the first premolar extraction, this wire is bent to pass passively through the canine and second premolar slots directly to the first molar band tube. It is indicated in cases of Class I relationships and never be used in the maxilla in other cases.

The design of this wire involves introducing three bends; the first one is located distal to the second premolar to like as the offset for the first molar, providing vertical flexibility. The second bend is located mesial to the second premolar in a verbal direction to prevent buccal movement of the canine, while the third is a lingual curve mesial to the bracket of the canine to minimize the trauma to the patient (Figure 19). Light intra-arch elastic (elastomeric power chain) retracts the canine part bodily and part tipping⁽²⁵⁾.

The anchorage can be gained from the headgear in the maxillary arch and banding the second molar in the lower arch. Nance button with or without the trans-palatal arch in the upper jaw and lingual arch in the lower jaw may provide satisfactory anchorage.

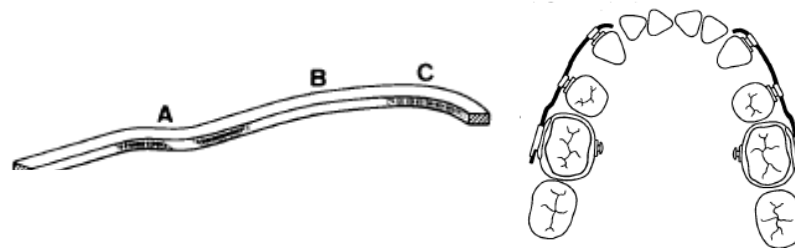


Figure 19: Sectional nickel-titanium archwire with elastomeric chain

Advantages

1. Compared with other sectional techniques, soft tissue trauma is very minimal.
2. Patients can accept such a design because it is easy to clean.
3. The construction, fitting, activation, and follow-up reactivation are simple and take less chair time.
4. The vertical distortion of the wire in the extraction site is little or absent.
5. Movement of the canine root distally can be achieved with a simple technique without causing an iatrogenic deep bite.
6. Many clinicians with different experience levels found it very effective and rapid in managing different clinical situations without time wasted in the alignment stage.

(3) Drum spring retractor

The drum retractor is designed by Darendeliler *et al.*⁽²⁶⁾ for individual canine retraction with one activation using constant light force (50 gm) without an archwire. It consists of four parts: a constant force spring with a hook principally designed and fabricated to apply 50 gm force, a drum, a spring box, and a central pin soldered to the molar band (Figure 20). Activation is performed by pulling the end of the spring.

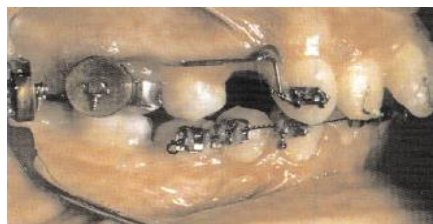

Figure 20: Drum spring retractor

Advantages

1. It can apply constant and continuous force.
2. No archwire is used with this spring.
3. It needs just one activation to close the extraction space.
4. Precise analysis of the force applied to move the canine can be performed.
5. Comfortable to the patient as soft tissue trauma or irritation is minimal because the point of force application is 6 mm. apical to the canine bracket slot, which leads to less tipping at the same time.

Disadvantage

1. Uncontrolled canine rotation is predicted with the absence of the guiding archwire.

(4) Canine retraction with rare earth magnets

Daskalogiannakis and McLachlan ⁽²⁷⁾ utilized the magnet forces in retracting canines by exerting a prolonged constant force that produces effective tooth movement. They used a special retraction assembly consisting of a vertical loop of 0.017×0.025 inch TMA wire, vestibular wire of 0.018×0.025 inch stainless steel wire that is inserted in the auxiliary tube of the molar band, and three Parylene coated Neodymium-Iron-Boron (Nd₂Fe₁₄P) block magnets of 2×3×5 mm in size.

The vestibular wire houses two magnets, the mesial and the distal, whereas the sectional wire of the vertical loop contains a helix between the second premolar and first molar that receives a middle magnet. The mesial and middle magnets were in repelling mode, whereas the distal and middle were in attractive mode. This will deliver constant force that activates the loop throughout canine retraction (Figure 21).

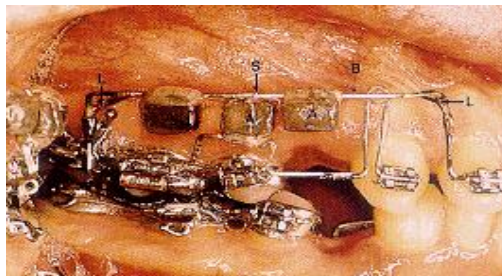

Figure 21: Canine retraction with rare earth magnets

Advantage

1. No reactivation of the loop is required.

Disadvantages

1. Complicated design that may irritate the cheek.
2. It needs special care and management by an expert clinician.

(5) Distraction of periodontal ligament

Liou and Huang ⁽²⁸⁾ utilized the concept of distraction osteogenesis to develop a method of rapid canine retraction called dental distraction using custom made intra-oral distraction device (containing one distraction screw, two guidance bars, and a special apparatus to activate the distractor by turning the screw clockwise) and three bone cuts.

Bands of 0.06×1.80 inch are seated on the canines, and the first molars and an impression are taken with the bands in place. In the lab., the distractor is soldered to the bands of the canine and first molar on the dental cast. The location and angulation of the distractor are adjusted according to the position of the canine. The distractor is usually positioned as high as possible to reduce tipping (Figure 22).

The procedure of canine retraction entails extraction of the first premolar and undermining the inter-septal bone distal to the canine by grooving two vertical cuts along the buccal and lingual sides with an oblique one toward the base of the inter-septal bone (in order to abate its resistance) using bone bur. The depth of these undermining grooves is determined by evaluating the thickness of the inter-septal bone using periapical X-ray film. Then a tooth-borne, custom-made device is placed to retract the canines into the extraction space.

The authors assumed a similarity between the process of osteogenesis in the periodontal ligament during orthodontic tooth movement and the distraction in the mid-palatine suture during rapid palatal expansion.

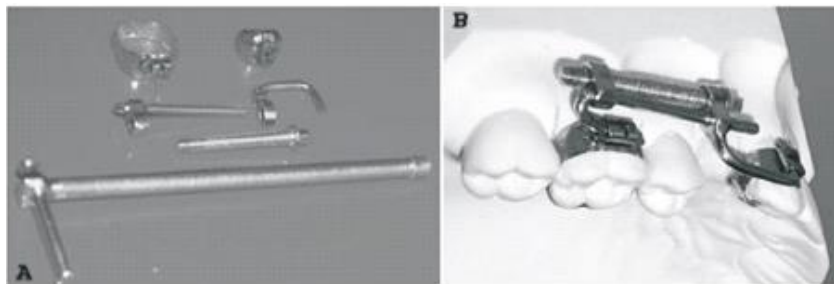


Figure 22: Canine retraction using distractor of periodontal ligament

Advantages

1. Rapid canine retraction within three weeks.
2. Minimal loss of anchorage.
3. Minimal effect on root resorption, the vitality of the pulp, and periodontal health.

Disadvantages

1. Needs a unique device for retraction.
2. Surgical intervention is required (traumatic).

Conclusions

Separate canine retraction with archwire is preferable in anterior teeth crowding and midline discrepancy as the action of trans-septal fibers observes remarkable improvement of anterior teeth crowding.

Various methods of canine retraction with the archwires were explained in detail regarding their advantages and disadvantages.

T-loop is the preferred spring of all because of its characteristics.

Conflict of interest: None.

References

1. Burstone, CJ., Choy, K. The biomechanical foundation of clinical orthodontics. 1sted. Chicago: Quintessence Publishing Co, Inc.; 2015.
2. Nanda, RS., Tosun, YS. Biomechanics in Orthodontics: Principles and Practice. 1st ed. Chicago: Quintessence Publishing Co, Inc.; 2010.
3. Charles, CR., Jones, ML. Canine retraction with the edgewise appliance- Some problems and solutions. Br J Orthod. 1982; 9(4): 194-202.
4. Drescher, D., Bourquel, C., Schumacher, H. Frictional forces between bracket and archwire. Am J Orthod Dentofacial Orthop. 1989; 96(5): 397-404.
5. Farrant, SD. An evaluation of different methods of canine retraction. Br J Orthod. 1977; 4(1): 5-15.
6. Bull, HL. Obtaining facial balance in the treatment of class II, division 1. Angle Orthod. 1951; 21(3): 139-148.
7. Modlin, SS. A light force edgewise technique to control anterior overbite by prior cuspid positioning. J Clin Orthod. 1979; 13(7): 457-471.
8. Burstone, CJ. Rationale of the segmented arch. Am J Orthod. 1962; 48(11): 805-822.
9. Ricketts, R., Bench, RW., Gugino, CF., et al. Bioprogressive Therapy. 1st ed. Rocky Mountain Orthodontics, Denver; 1978.
10. Burstone, CJ. The segmented arch approach to space closure. Am J Orthod. 1982; 82(5): 361-378.
11. Bourauel, C., Drescher, D., Ebling, J., et al. Superelastic nickel titanium alloy retraction springs-an experimental investigation of force systems. Eur J Orthod. 1997; 19(5): 491-500.
12. Ulgen, M. Ortodontik Tedavi Prensipleri. Ankara Universitesi Basimevi Boltlm 15 Ankara, 1983.
13. Dinger, M., Işcan, H. The effects of different sectional arches in canine retraction. Eur J Orthod. 1994; 16(4): 317-323.
14. Gjessing, P. Biomechanical design and clinical evaluation of a new canine-retraction spring. Am J Orthod. 1985; 87(5): 353-362.
15. Sander, F-G. Biomechanical investigation of the hybrid retraction spring. J Orofac Orthop. 2000; 61(5): 341-351.
16. Nanda, R. Esthetic and biomechanical strategies for clinical orthodontics. 1st ed. Philadelphia: WB Saunders; 2005.
17. Ladanyi, C. Dentaurem Website. <http://www.benlioglu.com/wp-content/uploads/2014/02/Dentaurem.pdf>.
18. Watanabe, Y., Miyamoto, K. A Nickel Titanium canine retraction spring. J Clin Orthod. 2002; 36(7): 384-388.
19. Vogt, W. The wave spring. J Clin Orthod. 2004; 38(5): 288-291.
20. Marcotte, MR. Biomechanics in orthodontics. 1st ed. Philadelphia: Deker; 1990.
21. Davis, S., Sundareswaran, S., James, J. Comparative evaluation of the efficiency of canine retraction using modified Marcotte and T-loop retraction springs – A split-mouth, randomized clinical trial. J Orthod Sci. 2019; 8(2): 9.
22. Mehrotra, P., Bhagchandani, J., Agarwal, S., et al. Three-dimensional canine loop for management of buccally erupted canines. APOS Trends Orthod. 2015; 5(5): 229-231.
23. Jain, AK., Agarwal, S., Warsi, F. Simultaneous torquing, aligning and retraction spring: A three-dimensional approach for blocked out canines. APOS Trends Orthod. 2016; 6(4): 232-234.

24. Aileni, KR., Rachala, MR., Prathima, CR., et al. Management of an unusual ectopic eruption of maxillary canine. J Clin Diagn Res. 2017; 11(5): ZD03-ZD05.
25. Orton, HS., McDonald, F. A simple sectional canine retraction technique using the properties of nickel titanium rectangular wire. Eur J Orthod. 1985; 7(2): 120-126.
26. Darendeliler, MA., Darendeliler, H., OktayÜner, O. The drum spring (DS) retractor: a constant and continuous force for canine retraction. Eur J Orthod. 1997; 19(2): 115-130.
27. Daskalogiannakis, J., McLachlan, KR. Canine retraction with rare earth magnets: An investigation into the validity of the constant force hypothesis. Am J Orthod Dentofacial Orthop. 1996; 109(5): 489-495.
28. Liou, EJW., Huang, CS. Rapid canine retraction through distraction of the periodontal ligament. Am J Orthod Dentofacial Orthop. 1998; 114(4): 372-381.

العنوان: الطرق المختلفة لسحب الناب- الجزء الثاني
 الباحثون: محمد ناهض ، ياسر عبد الكاظم ياسر
 المستخلص

الخلفية: الغرض من هذه المراجعة هو مناقشة تقنيات سحب الانياب المختلفة باستخدام ميكانيكا عدم الاحتكاك. الطرق: بين عامي 1930 و فبراير 2022 ، أجريت عمليات بحث حول تقنيات سحب الانياب المختلفة باستخدام أجهزة تقويم الأسنان الثابتة في مجموعة متنوعة من قواعد البيانات ، بما في ذلك **Science Direct** و **PubMed Central** ومكتبة **Wiley Online** ومكتبة **Cochrane** والكتب و **Google Scholar** و **Research Gate** و البحث اليدوي. النتائج: بعد إزالة المقالات المكررة ، تم تضمين المنشورات التي وصفت كيفية استخدام الأسلاك المقوسة لسحب الأنياب. الاستنتاجات: تمت مناقشة إيجابيات وسلبيات تقنيات سحب الانياب المختلفة باستخدام الأسلاك المقوسة. **T-loop** هو الزنبرك المفضل من الجميع بسبب خصائصه.