



University of Dundee

New and recurrent AAGAB mutations in punctate palmoplantar keratoderma

Pohler, Elizabeth; Huber, M.; Boonen, S. E.; Zamiri, M.; Gregersen, P. A.; Sommerlund, M.

Published in:
British Journal of Dermatology

DOI:
[10.1111/bjd.12927](https://doi.org/10.1111/bjd.12927)

Publication date:
2014

Document Version
Publisher's PDF, also known as Version of record

[Link to publication in Discovery Research Portal](#)

Citation for published version (APA):
Pohler, E., Huber, M., Boonen, S. E., Zamiri, M., Gregersen, P. A., Sommerlund, M., Ramsing, M., Hohl, D., McLean, W. H. I., & Smith, F. J. (2014). New and recurrent AAGAB mutations in punctate palmoplantar keratoderma. *British Journal of Dermatology*, 171(2), 433-436. <https://doi.org/10.1111/bjd.12927>

General rights

Copyright and moral rights for the publications made accessible in Discovery Research Portal are retained by the authors and/or other copyright owners and it is a condition of accessing publications that users recognise and abide by the legal requirements associated with these rights.

Take down policy

If you believe that this document breaches copyright please contact us providing details, and we will remove access to the work immediately and investigate your claim.

¹Department of Dermatology, Venereology and Allergy, University Medical Center, Theodor-Kutzer-Ufer 1-3, 68135 Mannheim, Germany

²Ruprecht-Karl-University of Heidelberg, Mannheim, Germany

³Skin Cancer Unit, German Cancer Research Center (DKFZ), Heidelberg, Germany

Correspondence: Martin Leverkus.

E-mail: martin.leverkus@medma.uni-heidelberg.de

A. OROUJI^{1,2}
S. GOERDT^{1,2}
J. UTIKAL^{1,2,3}
M. LEVERKUS^{1,2}

References

- 1 Epstein EH. Basal cell carcinomas: attack of the hedgehog. *Nat Rev Cancer* 2008; **8**:43–54.
- 2 Goppner D, Leverkus M. Basal cell carcinoma: from the molecular understanding of the pathogenesis to targeted therapy of progressive disease. *J Skin Cancer* 2011; **2011**:650258.
- 3 Leverkus M. Malignant epithelial tumors: Part I. Pathophysiology and clinical features. *J Dtsch Dermatol Ges* 2012; **10**:457–71.
- 4 Nitzki F, Becker M, Frommhold A et al. Patched knockout mouse models of basal cell carcinoma. *J Skin Cancer* 2012; **2012**:907543.
- 5 Sekulic A, Migden MR, Oro AE et al. Efficacy and safety of vismodegib in advanced basal-cell carcinoma. *N Engl J Med* 2012; **366**:2171–9.
- 6 Tang JY, Mackay-Wiggan JM, Aszterbaum M et al. Inhibiting the hedgehog pathway in patients with the basal-cell nevus syndrome. *N Engl J Med* 2012; **366**:2180–8.
- 7 Manousaridis I, Leverkus M. Malignant epithelial tumors: Part II. Therapy and prevention. *J Dtsch Dermatol Ges* 2013; **11**:9–25.
- 8 Aasi S, Silkiss R, Tang JY et al. New onset of keratoacanthomas after vismodegib treatment for locally advanced basal cell carcinoma: a report of 2 cases. *JAMA Dermatol* 2013; **149**:242–3.
- 9 Iarrobino A, Messina JL, Kudchadkar R, Sondak VK. Emergence of a squamous cell carcinoma phenotype following treatment of metastatic basal cell carcinoma with vismodegib. *J Am Acad Dermatol* 2013; **69**:e33–4.
- 10 Werner RN, Sammain A, Erdmann R et al. The natural history of actinic keratosis: a systematic review. *Br J Dermatol* 2013; **169**:502–18.

Funding sources: none.

Conflicts of interest: M.L. has received speaker's honoraria from Roche.

New and recurrent AAGAB mutations in punctate palmoplantar keratoderma

DOI: 10.1111/bjd.12927

DEAR EDITOR, Punctate palmoplantar keratoderma type I (PPPK1; also known as Buschke-Fischer-Brauer type; OMIM 148600) is an autosomal dominant disorder of keratinization, characterized by multiple hyperkeratotic lesions on the palms and soles that usually start in early adolescence but may also start later

in life.¹ Lesions increase in size and number with advancing age and may coalesce over pressure points to form larger plaques. Recently, two consecutive studies identified the causative gene for PPPK1 as AAGAB,^{2,3} located on chromosome 15q23, a locus to which the causal gene for PPPK1 was previously mapped.⁴ Subsequently, further mutations in AAGAB were described in families from several countries worldwide.^{5–11} In this study, we investigated five European families with a clinical diagnosis of PPPK1. This work was conducted in accordance with the principles of the Declaration of Helsinki. Blood was obtained following written informed consent and DNA extracted using standard protocols. Polymerase chain reaction amplification and Sanger sequencing to screen all exons and exon/intron boundaries of AAGAB was done as described previously.³

The 31-year-old proband from family 1, a four-generation family of Swiss origin (Fig. 1a), presented with small, horny nails and hyperkeratosis of the palms and soles. Age of onset was 7 years. Discrete punctate lesions were observed along the lateral edge of the plantar surface, with more extensive hyperkeratosis over the heels (Fig. 1b). Peeling skin was observed in the interdigital webspaces of the feet. The proband's father displayed extensive hyperkeratotic

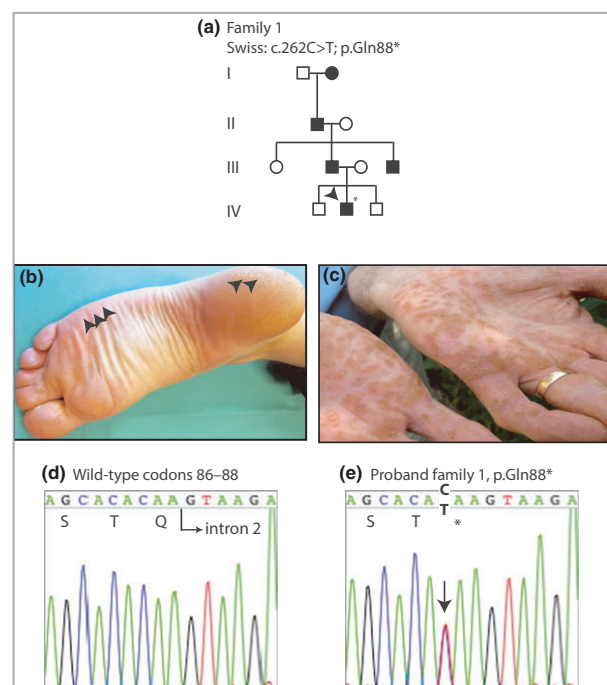


Fig 1. Pedigree, clinical images and mutation analysis of family 1. (a) Pedigree showing a four-generation history of punctate palmoplantar keratoderma. The arrowhead indicates the proband. (b) Punctate hyperkeratotic lesions (arrows) around the lateral edge of the foot and heel on the proband. (c) Palms of the father of the proband showing multiple hyperkeratotic lesions. (d) DNA sequence of codons 86–88 of AAGAB in an unaffected control sample. (e) The same region as in (d) from the proband of family 1. The arrow indicates the heterozygous C>T mutation at c.262 resulting in nonsense mutation p.Gln88*.

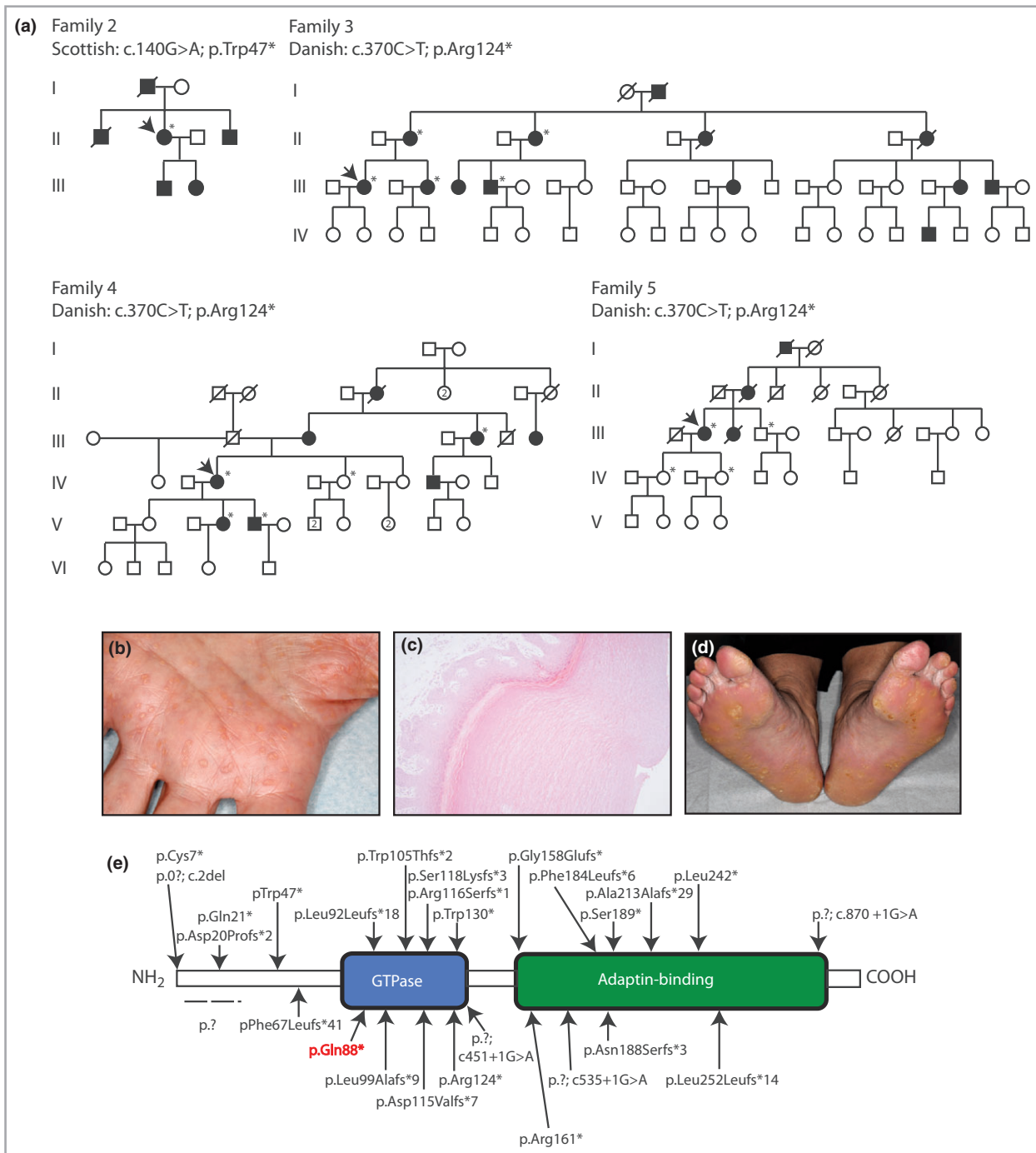


Fig 2. Pedigrees, clinical images and histology of punctate palmoplantar keratoderma type 1 families 2–5. (a) Pedigrees of the families with the relevant mutations indicated. Arrows denote the proband, and asterisks show individuals in whom AAGAB was sequenced. (b) The palm of the proband of family 3 showing the presence of multiple hyperkeratotic lesions. (c) Haematoxylin and eosin staining of a punch biopsy from palmar skin from the proband in family 3. This shows compact orthokeratosis with a defined central depression within the lesion. (d) The plantar surface of the index case in family 4. Hyperkeratotic lesions coalesce at pressure points. (e) Organization of the protein domains in p34 encoded by AAGAB, illustrating the location of all mutations reported to date. The p.Gln88* mutation highlighted in red is the novel mutation reported in this study.

lesions on his palms (Fig. 1c). We identified a previously unreported heterozygous nonsense mutation p.Gln88*; c.262C>T (Fig. 1d,e) within the GTPase domain of the p34 protein (Fig. 2e). This mutation is neither present in the Database of Single Nucleotide Polymorphisms ([http://www.](http://www.ncbi.nlm.nih.gov/SNP/)

<http://www.ncbi.nlm.nih.gov/SNP/>) nor in the Exome Variant Server (<http://evs.gs.washington.edu/EVS/>). The resulting haploinsufficiency in this family is consistent with the increase in cell proliferation seen in PPPK lesions, as reported previously.³

In family 2, a 72-year-old Scottish woman was one of four family members over three generations with palmoplantar keratoderma (Fig. 2a). She presented with a 1-year history of worsening hyperkeratosis affecting primarily her soles. Small hyperkeratotic lesions were seen on her fingers but not on her palms. Both her children were affected, with hyperkeratosis developing at a much younger age than in herself. Her two brothers were similarly affected, and her deceased father was reported to have been affected. A recurrent heterozygous nonsense mutation, p.Trp47*; c.140G>A,^{3,5} within the N-terminal domain of p34 (Fig. 2e), was identified in the proband.

The other three families studied were apparently unrelated Danish kindreds. The 44-year-old proband of family 3 (Fig. 2a) developed dry palmar skin in her childhood progressing to punctate keratosis on the palms (Fig. 2b) and subsequently the soles. Haematoxylin and eosin staining of a biopsy from palmar skin (Fig. 2c) showed compact orthokeratosis with pronounced hyperkeratosis. A central dermal depression characteristic for punctate palmoplantar keratoderma was observed. A recurrent heterozygous nonsense mutation Arg124*; c.370C>T² was identified in the proband and four other affected members of this four-generation kindred (Fig. 2a). PPPK1 was reported in four generations of family 4 (Fig. 2a). The proband, a 53-year-old Danish female developed PPPK1 at 18–20 years of age. It gradually became worse, especially at pressure points on the feet (Fig. 2d) where punctate lesions coalesced. The palms and volar sides of the fingers were affected to a lesser degree. The same p.Arg124* mutation as in family 3 was identified in the proband, her affected daughter, son and aunt but not in an unaffected sister (Fig. 2a). In family 5, PPPK1 developed around the age of 20 years and progressed thereafter in the 68-year-old Danish proband. She presented with severe, very painful punctate palmoplantar keratoderma on the pressure points of her soles. Palms were also affected with multiple 3–5-mm punctate keratosis. Heterozygous nonsense mutation p.Arg124* was also identified in this individual. Three unaffected members did not carry the mutation (Fig. 2a).

PPPK1, an autosomal dominant disorder characterized by multiple hyperkeratotic lesions on the palms and soles, can vary in severity from mild to severe, and can be painful and socially debilitating. Recently, mutations have been described in the AAGAB gene, which encodes the α - and γ -adaplin binding protein p34, and has been proposed to have a role in skin integrity.² p34 has been functionally implicated in the intracellular transport of clathrin-coated vesicles,³ and may affect cell signalling via regulation of the expression of receptor tyrosine kinases, which are turned over by clathrin- and AP2-dependant mechanisms.^{3,5,12,13} Recently a mutation was reported in AAGAB in a Jewish family of Dutch origin with PPPK1 co-segregating with congenital dislocation of the hip.¹⁰ Whether this is a coincidence or if AAGAB has an as yet unknown role in skeletal development is unclear.

This study has revealed one novel, p.Gln88*, and two recurrent, p.Trp47* and p.Arg124*, mutations. This brings

the total to 27 distinct loss-of-function mutations reported in AAGAB (Fig. 2e), providing further evidence for this being the causative gene for PPPK1.

Acknowledgments

We thank all the patients for their participation in this study.

¹Centre for Dermatology and Genetic Medicine, Colleges of Life Sciences and Medicine, Dentistry and Nursing, University of Dundee, Dundee, U.K.

²Department of Dermatology, University Hospital of Lausanne (CHUV), Lausanne, Switzerland

³Department of Clinical Genetics, Aarhus University Hospital, Aarhus, Denmark

⁴Department of Dermatology, University Hospital Crosshouse, Kilmarnock, U.K.

⁵Alan Lyell Centre for Dermatology, Southern General Hospital, Glasgow, U.K.

⁶Department of Clinical Genetics, Aalborg University Hospital, Aalborg, Denmark

⁷Department of Dermatology and Venerology, and ⁸Department of Pathology, Aarhus University Hospital, Aarhus, Denmark

Correspondence: F.J.D. Smith.
E-mail: f.j.d.smith@dundee.ac.uk

References

- Emmert S, Küster W, Hennies HC et al. 47 individuals in 14 families with the rare genodermatosis keratosis punctata palmopantaris Buschke-Fischer-Brauer. *Eur J Dermatol* 2003; **1**:16–20.
- Giehl KA, Eckstein GN, Pasternack SM et al. Nonsense mutations in AAGAB cause punctate palmoplantar keratoderma type Buschke-Fischer-Brauer. *Am J Hum Genet* 2012; **91**:754–9.
- Pohler E, Mamai O, Hirst J et al. Haploinsufficiency for AAGAB causes clinically heterogeneous forms of punctate palmoplantar keratoderma. *Nat Genet* 2012; **44**:1272–6.
- Martinez-Mir A, Zlotogorski A, Londono D et al. Identification of a locus for type 1 punctate palmoplantar keratoderma on chromosome 15q22–q24. *J Med Genet* 2003; **40**:872–8.
- Pohler E, Zamiri M, Harkins CP et al. Heterozygous mutations in AAGAB cause type 1 punctate palmoplantar keratoderma with evidence for increased growth factor signalling. *J Invest Dermatol* 2013; **133**:2805–8.
- Kiritis D, Chmel N, Arnold AW et al. Novel and recurrent AAGAB mutations: clinical variability and molecular consequences. *J Invest Dermatol* 2013; **133**:2483–6.
- Li M, Yang L, Shi H et al. Loss of function mutation in AAGAB in Chinese families with punctate palmoplantar keratoderma. *Br J Dermatol* 2013; **169**:168–71.
- Cui H, Gao M, Wang W et al. Six mutations in AAGAB confirm its pathogenic role in Chinese punctate palmoplantar keratoderma patients. *J Invest Dermatol* 2013; **133**:2631–4.
- Li M, Dai X, Cheng R et al. A novel 5-bp deletion mutation in AAGAB gene in a Chinese family with palmoplantar keratoderma. *Acta Derm Venereol* 2014; **94**:339–40.

- 10 Eytan O, Sarig O, Israeli S et al. A novel splice-site mutation in the AAGAB gene segregates with hereditary punctate palmoplantar keratoderma and congenital dysplasia of the hip in a large family. *Clin Exp Dermatol* 2014; **39**:182–6.
- 11 Furniss M, Higgins CA, Martinez-Mir A et al. Identification of distinct mutations in AAGAB in families with type I punctate palmoplantar keratoderma. *J Invest Dermatol* 2014; **134**:1749–52.
- 12 Ceresa BP. Regulation of EGFR endocytic trafficking by rab proteins. *Histol Histopathol* 2006; **21**:987–93.
- 13 Rappaport JZ, Simon SM. Endocytic trafficking of activated EGFR is AP-2 dependent and occurs through preformed clathrin spots. *J Cell Sci* 2009; **122**:1301–5.

Funding sources: The Centre for Dermatology and Genetic Medicine at the University of Dundee is supported by a Wellcome Trust Strategic Award (098439/Z/12/Z to W.H.I.M.). This work was also supported by a Wellcome Trust Programme Grant (092530/Z/10/Z to W.H.I.M.).

Conflicts of interest: none declared.

Body mass index, waist circumference and HOMA-IR correlate with the Psoriasis Area and Severity Index in patients with psoriasis receiving phototherapy

DOI: 10.1111/bjd.12914

DEAR EDITOR, An increased incidence of obesity in patients with psoriasis has been documented in cross-sectional studies of large healthcare databases and case-control studies.^{1–7} Obesity, and in particular centripetal obesity, confers a risk of developing insulin resistance and type 2 diabetes, which in turn increases the risk of cardiovascular disease. Since 1978 it has been known that patients with psoriasis have higher rates of type 2 diabetes and cardiovascular disease and it is likely that this is driven by obesity and concomitant insulin resistance.

We undertook a study to establish the effect of body mass index (BMI), abdominal obesity and insulin resistance on psoriasis severity and Framingham risk. Following ethical approval, consecutive patients with psoriasis, aged ≥ 18 years, were recruited prior to commencing phototherapy or photochemotherapy (TL-01 or psoralen plus ultraviolet A) between

October 2008 and July 2011. Patients had a full physical examination and the Psoriasis Area and Severity Index (PASI) score was recorded. Height, weight and waist circumference were measured for each patient. The BMI was calculated using the formula: weight in kg/(height in m)². Obesity was defined as a BMI > 30 , overweight as BMI 25–30 and lean as a BMI < 25 according to the World Health Organization definition of obesity. Systolic blood pressure was measured using a sphygmomanometer on the left brachial artery. Fasting blood samples were taken for the measurement of insulin, glucose and serum cholesterol. Insulin resistance was measured using the homeostasis model with the formula: insulin \times glucose/22.5 (HOMA-IR, homeostatic model assessment–insulin resistance). Framingham risk was calculated using MedCalc[®] (MedCalc Software, Ostend, Belgium). Results were analysed using GraphPad Prism (GraphPad Software Inc., La Jolla, CA, U.S.A.), using Student's t-test, ANOVA and Pearson's rank correlation.

A total of 103 patients were recruited from the phototherapy department [mean age 40 years (range 21–69); mean PASI 9.6 (range 3–22.8); 52 male and 51 female]. When categorized according to their BMI into lean (BMI < 25 kg m⁻²), overweight (BMI 25–30 kg m⁻²) and obese (BMI > 30 kg m⁻²), 30% of the patients due to commence phototherapy were obese. Obese patients had significantly more severe psoriasis than the lean or overweight patients when categorized according to BMI ($n = 96$, $P = 0.002$) or according to waist circumference ($n = 90$, $P = 0.03$) (Fig. 1).

There was a significant correlation between BMI and PASI in patients prior to phototherapy ($n = 97$, $r = 0.33$, $P = 0.001$) (Fig. 2). When factors such as alcohol, smoking and stress were controlled for in a multiple regression analysis, the relationship between BMI and PASI remained significant ($P = 0.0005$). PASI was also associated with waist circumference ($n = 103$, $r = 0.34$, $P = 0.0009$). Abdominal obesity is associated with diabetes, which has an increased prevalence in patients with psoriasis. PASI was associated with fasting insulin ($n = 85$, $r = 0.48$, $P = 0.001$) and insulin resistance as measured using HOMA-IR ($n = 64$, $r = 0.48$, $P = 0.001$) in patients receiving phototherapy. Patients with a diagnosis of diabetes were excluded from this analysis. There was also a positive correlation between Framingham risk and BMI using Pearson's correlation ($n = 89$, $r = 0.24$, $P = 0.02$)

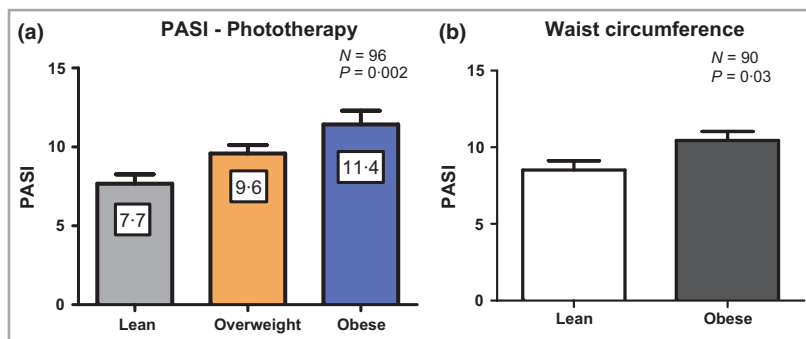


Fig 1. Obese patients prior to phototherapy had significantly more severe psoriasis than lean patients when compared using (a) body mass index (BMI) ($P = 0.002$) and (b) waist circumference ($P = 0.03$). Lean, BMI < 25 kg m⁻²; overweight, BMI 25–30 kg m⁻²; obese, BMI > 30 kg m⁻²; PASI, Psoriasis Area and Severity Index.