



**University of Dundee**

## **Multiple endocrine neoplasia**

Newey, Paul J.

*Published in:*  
Medicine

*DOI:*  
[10.1016/j.mpmed.2021.06.003](https://doi.org/10.1016/j.mpmed.2021.06.003)

*Publication date:*  
2021

*Licence:*  
CC BY-NC-ND

*Document Version*  
Peer reviewed version

[Link to publication in Discovery Research Portal](#)

*Citation for published version (APA):*  
Newey, P. J. (2021). Multiple endocrine neoplasia. *Medicine*, 49(9), 539-543.  
<https://doi.org/10.1016/j.mpmed.2021.06.003>

### **General rights**

Copyright and moral rights for the publications made accessible in Discovery Research Portal are retained by the authors and/or other copyright owners and it is a condition of accessing publications that users recognise and abide by the legal requirements associated with these rights.

- Users may download and print one copy of any publication from Discovery Research Portal for the purpose of private study or research.
- You may not further distribute the material or use it for any profit-making activity or commercial gain.
- You may freely distribute the URL identifying the publication in the public portal.

### **Take down policy**

If you believe that this document breaches copyright please contact us providing details, and we will remove access to the work immediately and investigate your claim.

## Multiple endocrine neoplasia

Paul J Newey

**Paul J Newey MB ChB BSc DPhil MRCP** is a Senior Lecturer in Endocrinology and Honorary Consultant Physician at the University of Dundee, UK. His research focuses on understanding the genetic basis of endocrine disorders. Competing interests: he has received speaker and/or consultancy fees from Ipsen, Sanofi and Lilly.

### Key Points

- The possibility of multiple endocrine neoplasia (MEN) should be considered in all patients presenting with apparently sporadic MEN-associated tumours, and a detailed family history obtained to establish evidence of a hereditary disorder
- Genetic testing should be offered to all individuals with a likely clinical diagnosis of MEN1 or MEN2 (i.e. *MEN1* and *RET* mutational analysis, respectively). For MEN2, this includes all patients with medullary thyroid cancer (MTC). Genetic testing should be offered to all first-degree relatives of affected individuals
- Patients at risk of developing MEN1 (i.e. *MEN1* mutation carriers) should be offered periodic clinical, biochemical and radiological screening to enable the early detection of tumours
- Patients at risk of developing MEN2 (i.e. *RET* mutation carriers) should be undergo periodic clinical, biochemical and radiological evaluation, and, where appropriate, be offered early prophylactic thyroidectomy, according to the risk category of *RET* mutation
- Treatment of MEN1 and MEN2 should aim to minimize the morbidity and mortality associated with disease, while maintaining the patient's quality of life. Management is often complex and requires multidisciplinary involvement

### Keywords

Genetic testing; hereditary disease; medullary thyroid cancer (MTC); pancreatic neuroendocrine tumour; parathyroid tumour; pheochromocytoma; pituitary adenoma

### Abstract

Multiple endocrine neoplasia (MEN) describes the occurrence of tumours affecting two or more endocrine glands in one patient. Two main forms are recognized: MEN type 1 (MEN1) and type 2 (MEN2). MEN1 is characterized by the combined occurrence of parathyroid, pituitary and pancreatic neuroendocrine tumours, whereas MEN2 features medullary thyroid cancer in association with pheochromocytoma and parathyroid tumours. Although both MEN1 and MEN2 are autosomal dominant disorders, they have contrasting molecular aetiologies: MEN1 results from inactivating germline mutations of the *MEN1* tumour suppressor gene, whereas MEN2 results from activating mutations in the *RET* proto-oncogene. The clinical features arising of each relate to the location of tumour development and/or hormonal hypersecretion, while treatment approaches aim to minimize morbidity and mortality, and preserve quality of life. Genetic testing is a key component of management, not only to confirm the diagnosis in affected patients, but also to identify family members who are at risk of disease but may be asymptomatic. It is recommended that patients 'at risk' of developing MEN1 and MEN2 (i.e. mutation carriers) undergo periodic clinical, biochemical and radiological surveillance to enable the early identification and/or treatment of tumours. Here, a brief overview of MEN1 and MEN2 is provided.

## Multiple endocrine neoplasia type 1 (MEN1)

### Definitions and epidemiology

MEN1 is characterized by the combined occurrence of parathyroid, pituitary and duodenopancreatic neuroendocrine tumours. A spectrum of additional tumours is reported, including thymic and bronchial carcinoids, adrenocortical tumours, and tumours affecting the skin and soft tissues (Table 1). The diagnosis of MEN1 can be established clinically (i.e. patient with  $\geq 2$  relevant endocrine tumours) or genetically (i.e. an individual with or without clinical manifestations harbouring a *MEN1* mutation).<sup>1</sup> The estimated incidence is approximately 1 in 30,000. It is associated with premature mortality, with around 30–70% of affected patients dying from causes related to the disorder.

### Pathology and pathogenesis

MEN1 is an autosomal dominant disorder caused by germline mutation of the *MEN1* gene, such that first-degree relatives of an affected individual have a 50% chance of inheriting the *MEN1* mutation. However, in around 5–10% of cases, the *MEN1* mutation occurs *de novo* so an affected individual has unaffected parents. The *MEN1* gene is located at chromosome 11q13.1 and encodes the protein menin. Most *MEN1* mutations result in loss of menin function (e.g. nonsense or frameshift mutations), while MEN1-associated tumours typically demonstrate bi-allelic *MEN1* inactivation consistent with a tumour suppressor function. Although menin is reported to influence many cellular processes (e.g. activation and repression of gene transcription, modulation of cellular signalling pathways), the molecular mechanisms leading to tumorigenesis remain ill-defined.

### Disease course

MEN1 is a highly penetrant disorder with virtually all patients (>98%) expressing disease by the fifth decade. However, no genotype–phenotype correlation exists, so it is not possible to predict the onset or spectrum of tumours in a given individual. Symptomatic presentations are unusual in early childhood (e.g. <10 years of age), although the earliest reported cases of MEN1-associated hyperparathyroidism, pituitary adenoma and pancreatic neuroendocrine tumour (PNET) are at 4, 5 and 5 years of age, respectively.<sup>1,2</sup> By 21 years of age, the penetrance of these tumours is reported to reach approximately 75%, 35% and 20–25%, respectively.<sup>2</sup> Hyperparathyroidism is often the first manifestation of disease, although a minority present with a PNET, pituitary tumour or other MEN1-associated tumour (e.g. thymic carcinoid).<sup>2</sup>

### Clinical features and treatment

**Parathyroid tumours:** primary hyperparathyroidism occurs in >95% of MEN1 patients, demonstrates an equal sex distribution, and typically manifests synchronous or asynchronous involvement of all four glands. Patients are frequently asymptomatic with mild hypercalcaemia, although symptomatic disease can occur and relates to hypercalcaemia (e.g. thirst, polyuria, constipation) or disease complications (e.g. nephrolithiasis, osteitis fibrosa cystica). Surgery is the treatment of choice, with most experts advocating subtotal (i.e. removal of  $\geq 3.5$  glands) or total parathyroidectomy.<sup>1</sup>

**Pituitary tumours:** the incidence of pituitary tumours in MEN1 is estimated to be 30–40%, with most occurring as microadenomas (<1 cm diameter). Prolactinomas represent the most common functioning tumour, although somatotropinomas and corticotropinomas also occur. The remainder comprise clinically non-functioning adenomas. Symptoms relate to hormonal hypersecretion or local mass effects (e.g. hypopituitarism, visual field defect). Treatment is the same as for sporadic counterparts (e.g. trans-sphenoidal surgery, dopamine agonist for prolactinoma).

**Pancreatic neuroendocrine tumours:** clinically significant PNETs occur in around 30–80% of patients with MEN1 and are the leading cause of premature mortality. Patients can harbour multiple tumours, and attempts to correlate imaging findings with symptoms and/or biochemical evidence of hormone hypersecretion can be confounded.<sup>3</sup>

*Functioning tumours* – gastrinomas occur in 30–40% of patients with MEN1. Untreated, they are associated with gastric acid hypersecretion, recurrent peptic ulceration and haemorrhage (Zollinger–Ellison syndrome). Most MEN1-associated gastrinomas are small (<1 cm) and multiple, and occur in the duodenal mucosa. Surgical resection of duodenal gastrinomas is controversial as good long-term outcomes are reported with medical therapy alone (e.g. proton pump inhibitors).<sup>3</sup> Insulinomas affect 10–30% of MEN1 patients and often occur at a young age (around 10–15% penetrance by 21 years of age). Typically, they present with symptomatic hypoglycaemia, and curative surgery is the treatment of choice. Other functioning PNETs (e.g. glucagonomas, VIPomas) occur rarely.

*Non-functioning PNETs (NF-PNETS)* – these are recognized as the most common PNETs in MEN1, occurring in 30–60% of individuals. Presentations in early childhood are rare, but recent series indicate a

prevalence of 10–40% by around 20 years of age. Diagnosis typically relies on imaging (e.g. endoscopic ultrasound, magnetic resonance imaging) as patients are often asymptomatic and tumour markers (e.g. chromogranin A) unreliable.<sup>3</sup> The risk of metastatic disease is related to tumour diameter, with most clinicians recommending surgery for NF-PNETS of >2 cm, although some advocate lower cut-offs.<sup>1,3</sup> Systemic therapies (e.g. somatostatin analogues, tyrosine kinase inhibitors) and locoregional approaches (e.g. cytoreductive surgery, radiofrequency ablation) are used for advanced disease.

**Other MEN1-associated tumours:** adrenocortical tumors occur in approximately 20% of patients. Most are small (<1 cm) and non-functioning, although a minority are hormone-secreting (e.g. resulting in primary hyperaldosteronism or Cushing's syndrome). Adrenocortical carcinoma is occasionally reported. Thymic and bronchial carcinoid tumors occur in 2–8% of patients with MEN1. Thymic carcinoids, occurring predominantly in men, are associated with an aggressive disease course, while bronchial carcinoids have more favourable outcomes.

### Genetic testing

MEN1 genetic testing should be offered to all patients with a clinical diagnosis of MEN1, all first-degree relatives of affected individuals (symptomatic and asymptomatic), and individuals with an increased likelihood of disease (e.g. multiple PNETs, sporadic gastrinoma, recurrent or multigland parathyroid disease). Establishing a genetic diagnosis of MEN1 is important for several reasons: first, to confirm the clinical diagnosis; second, to facilitate the identification of first-degree relatives who carry the *MEN1* mutation; and finally, to identify family members who do not harbour the mutation and can be reassured. Notably, around 5–10% of patients with MEN1 do not have mutations in the *MEN1* coding region; these individuals can harbour mutations in non-coding regions or mutations in other genes. For example, a small number of kindreds with an MEN1-like phenotype have been identified to harbour mutations in the cyclin-dependent-kinase inhibitor 1B (*CDKN1B*) gene, a condition referred to as MEN type 4.

### Organization of care and screening

Individuals with a clinical or genetic diagnosis of MEN1 should be cared for by a multidisciplinary team with appropriate expertise. Current guidelines recommend that individuals at high risk of disease (i.e. *MEN1* mutant gene carriers) undergo periodic clinical, biochemical and radiological screening to identify tumours at an early stage (Table 2). Given the potential complexities of management, the patient (or relevant carer) should be involved in decisions regarding care.

## Multiple endocrine neoplasia type 2 (MEN2)

### Definition and epidemiology

MEN2 is characterized by the occurrence of medullary thyroid carcinoma (MTC), together with pheochromocytoma and parathyroid adenomas. MEN2 is categorized into two main syndromes: MEN2A and MEN2B. MEN2A accounts for 90–95% of cases and describes MTC in association with pheochromocytoma and parathyroid tumors, although some families only manifest MTC (i.e. 'familial MTC'). MEN2B is less frequent, representing around 5–10% of MEN2 cases. It describes MTC and pheochromocytoma in association with a marfanoid habitus, mucosal neuromas, medullated corneal fibres and intestinal autonomic ganglion dysfunction. Collectively, the reported incidence of MEN2 is 1 in 80,000 live births.

### Pathology and pathogenesis

MEN2 is an autosomal dominant disorder resulting from germline mutations in the rearranged during transfection (*RET*) proto-oncogene (located at chromosome 10q11.2), which encodes a tyrosine kinase receptor expressed in neural crest cells (e.g. thyroid C cells, adrenal medullary cells).<sup>4</sup> MEN2 can occur in the absence of affected family members as *de novo RET* mutations are observed in around 5–10% and around 75% of MEN2A and MEN2B cases, respectively. Most cases of MEN2A result from missense substitutions affecting one of a small number of highly conserved cysteine residues, while around 95% of individuals with MEN2B harbour a methionine to threonine substitution affecting codon 918 (Figure 1). Thus, MEN2 displays a strong genotype–phenotype correlation such that the specific *RET* mutation predicts the timing and behavior of MTC and the occurrence of associated endocrine manifestations (Table 3).<sup>5</sup>

### Clinical features

**Medullary thyroid carcinoma:** MTC, arising from thyroid parafollicular C cells, is highly penetrant in MEN2 (70–100% of patients) and remains the major determinant of premature mortality.<sup>4,5</sup> Typically, MTC is the first manifestation of disease in MEN2A, affected individuals presenting with a neck mass. Additional symptoms can include diarrhoea and or flushing, while lymph node and distant metastases often occur at

presentation. The diagnosis of MTC is based on the demonstration of high serum calcitonin concentrations combined with appropriate radiological and/or cytological evidence of tumour occurrence. Where possible, curative surgical resection is the treatment of choice. For patients with advanced disease, external-beam radiotherapy, radionuclide therapy and tyrosine kinase inhibitors are used.

**Phaeochromocytoma:** this can occur in individuals with MEN2A and MEN2B. In MEN2A, it typically presents in the third or fourth decade, with symptoms of catecholamine excess including episodic sweating, palpitations, headache and anxiety. The diagnosis and treatment of phaeochromocytoma is the same as for sporadic disease, although the possibility of bilateral disease should be considered.

**Primary hyperparathyroidism:** a minority of MEN2A patients develop primary hyperparathyroidism, which is often mild. Several glands can be affected, with treatment aimed at removal of enlarged glands.

**Genetic testing: indications and implications**

Germline *RET* genetic testing should be performed in all patients with a clinical diagnosis of MEN2 or apparently sporadic MTC or phaeochromocytoma, as well as in first-degree relatives of known *RET* mutation carriers. The ability to make a genetic diagnosis of MEN2, often in early childhood, before the onset of clinical features, enables the appropriate monitoring and treatment of asymptomatic individuals. Prophylactic thyroidectomy is typically recommended in early childhood for those 'at risk' of developing hereditary MTC (i.e. *RET* mutation carriers), although the timing of surgery varies according to the risk category of *RET* mutations (Table 3).<sup>5</sup> Screening for phaeochromocytoma and hyperparathyroidism is also recommended (Table 3).<sup>5</sup>

## KEY REFERENCES

1. Thakker RV, Newey PJ, Walls GV, et al. Clinical practice guidelines for multiple endocrine neoplasia type 1 (MEN1). *J Clin Endocrinol Metab* 2012; **97**: 2990–3011.
2. Goudet P, Dalac A, Le Bras M, et al. MEN1 disease occurring before 21 years old: a 160-patient cohort study from the Groupe d'etude des Tumeurs Endocrines. *J Clin Endocrinol Metab* 2015; **100**: 1568–77.
3. Yates CJ, Newey PJ, Thakker RV. Challenges and controversies in management of pancreatic neuroendocrine tumours in patients with MEN1. *Lancet Diabetes Endocrinol* 2015; **3**: 895–905.
4. Waguespack SG, Rich TA, Perrier ND, Jimenez C, Cote GJ. Management of medullary thyroid carcinoma and MEN2 syndromes in childhood. *Nat Rev Endocrinol* 2011; **7**: 596–607.
5. Wells SA, Jr, Asa SL, Dralle H, et al. Revised American Thyroid Association guidelines for the management of medullary thyroid carcinoma. *Thyroid* 2015; **25**: 567–610.

**Table 1 Clinical features of MEN1**

<b>Primary hyperparathyroidism (&gt;95%)</b>
• Parathyroid adenoma/hyperplasia (>95%)
• Parathyroid carcinoma (very rare)
<b>Pancreatic neuroendocrine tumours (PNETs) (30–80%)</b>
• Gastrinoma <sup>a</sup> (30–40%)
• Insulinoma (10–30%)
• Glucagonoma (<3%)
• VIPoma (very rare)
• Non-functioning PNET (30–60%)
<b>Pituitary adenomas (30–40%)</b>
• Prolactinoma (20%)
• Somatotropinoma (<10%)
• Corticotropinoma (<5%)
• Non-functioning adenoma (10–25%)
<b>Foregut neuroendocrine tumours (NETs)</b>
• Thymic NET (2–8%)
• Bronchial NET (<5%)
• Gastric NET ('ECLoma' <sup>b</sup> ) (10%)
<b>Adrenocortical tumours (10–20%)</b>
• Conn's adenoma (around 1%)
• Cortisol-secreting adenoma (around 1%)
• Pheochromocytoma (very rare)
• Non-functioning adenoma (10–20%)
• Adrenocortical carcinoma (around 1%)
<b>Miscellaneous tumours</b>
• Lipomas (30%)
• Angiofibromas (85%)
• Collagenomas (70%)
• Meningiomas (around 5%)
• Ependymomas (<5%)
• Breast cancer (increased relative risk reported)

<sup>a</sup>Most gastrinomas are located in the duodenal mucosa.

<sup>b</sup>'ECLoma' refers to tumours arising from enterochromaffin-like cells, which are observed in patients with hypergastrinaemia caused by Zollinger–Ellison syndrome.

**Table 2 Suggested screening guidelines for individuals at risk of MEN1**

<b>MEN1-associated tumour</b>	<b>Age to begin screening (years)</b>	<b>Biochemical screening test (annually)</b>	<b>Imaging screening test (time interval)</b>
<b>Parathyroid</b>	8	Calcium, PTH	None
<b>Pancreatic</b>			
Gastrinoma	20	Fasting gastrin	None
Insulinoma	5	Fasting glucose ( $\pm$ insulin)	None
Other PNET (e.g. non-functioning)	10	Chromogranin A, gastrointestinal hormone profile <sup>a</sup> (e.g. glucagon, pancreatic polypeptide vasoactive intestinal peptide)	MRI abdomen, EUS (annually)
<b>Pituitary</b>			
Prolactinoma	5	Prolactin	None
Somatotropinoma	5	Insulin-like growth factor 1	None
Other pituitary adenoma (e.g. non-functioning NET)	10 <sup>b</sup>	None, unless signs or symptoms of functioning tumour (e.g. corticotroph adenoma)	MRI pituitary (every 3 years)
<b>Adrenocortical</b>	<10	None, unless signs or symptoms of functioning tumour or tumour >1 cm on imaging	MRI abdomen (annually)
<b>Thymic/bronchial carcinoid</b>	15	None	CT or MRI chest (every 1–2 years)

<sup>a</sup>Although chromogranin A, pancreatic polypeptide and glucagon concentrations can be elevated with NF-PNETs, they have low sensitivity and specificity such that their value is debated.

<sup>b</sup> Although pituitary tumours are reported in MEN1 patients as young as 5 years of age, in the absence of symptoms, signs or biochemical evidence of a pituitary adenoma, pituitary imaging may be delayed until >10 years of age to coincide with pancreatic imaging.

CT, computer tomography; EUS, endoscopic ultrasound; MRI, magnetic resonance imaging; PTH, parathyroid hormone.

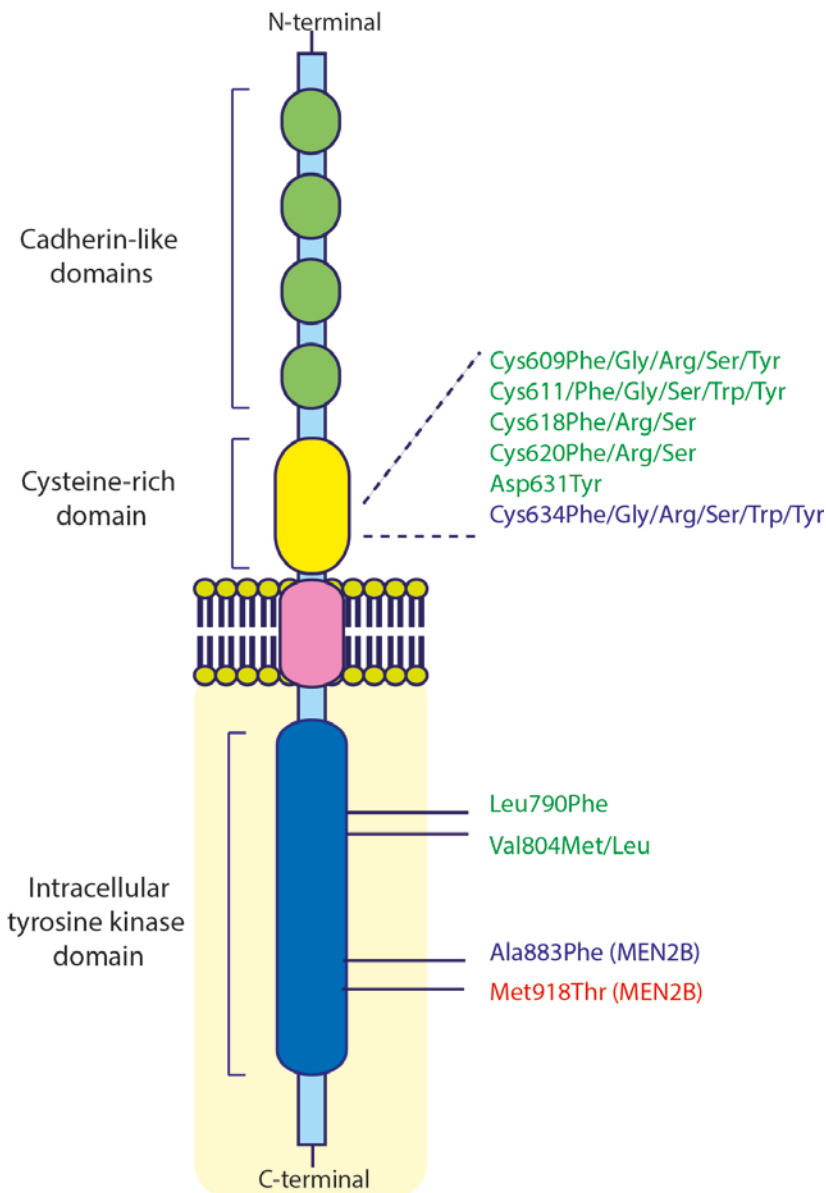


**Table 3 Suggested screening and treatment guidelines for individuals at risk of MEN2**

		<b>American Thyroid Association MTC risk category of <i>RET</i> mutation<sup>a</sup></b>		
		<b>Highest</b>	<b>High</b>	<b>Moderate</b>
	<b>Relevant <i>RET</i> mutations</b>	Met918Thr	Codon 634 mutations Ala883Phe	All other validated pathogenic mutations
<b>Recommended age to commence screening / undertake intervention</b>	<b><i>RET</i> genetic testing</b>	ASAP and by <1 year	<3 years	<3-5 years
	<b>MTC</b>			
	First serum calcitonin/neck ultrasound	ASAP (by <0.5–1 year)	3 years	5 years
	Prophylactic thyroidectomy	ASAP (by <1 year)	5 years or earlier	>5 years
	<b>Phaeochromocytoma</b>	11 years	11 years	16 years
	<b>Primary hyperparathyroidism</b>	–	11 years	16 years

<sup>a</sup>Risk category of *RET* mutation and screening and treatment schedule based on the Revised American Thyroid Association Guidelines for the Management of Medullary Thyroid Carcinoma.<sup>5</sup>

**Figure 1**



RET receptor structure and location of common MEN2-associated *RET* mutations. The RET receptor is a membrane-associated tyrosine kinase receptor expressed in cells of neural crest origin. MEN2-associated mutations arise most frequently in the cysteine-rich region of the extracellular domain, or in the intracellular domain associated with intrinsic tyrosine kinase activity, resulting in enhanced receptor signalling. *RET* mutations are described according to the respective missense substitution, with amino acids represented using standard nomenclature. The American Thyroid Association<sup>5</sup> risk category of each *RET* mutation is represented by colour; red, 'highest' risk; blue, 'high' risk; green, 'moderate' risk. Mutations associated with MEN2B are noted in parentheses.

## TEST YOURSELF

To test your knowledge based on the article you have just read, please complete the questions below. The answers can be found at the end of the issue or online [here](#).

### Question 1

A 43-year old man presented with biochemical evidence of hyperparathyroidism. Initial investigations with neck ultrasound and parathyroid sestamibi scan indicated a single right-sided parathyroid adenoma. He underwent curative surgery with the removal of a right inferior parathyroid adenoma. There were no other clinical symptoms or signs of additional endocrine disease, and no other past medical history of note.

**Which of the following should be performed initially to investigate the possibility of multiple endocrine neoplasia?**

- A. Germline *MEN1* genetic testing.
- B. Germline *RET* genetic testing.
- C. Biochemical evaluation for likely tumours
- D. Take a relevant family history
- E. MR scan of pituitary and abdomen, CT scan of chest

**Answer: D.** In the absence of a relevant family history, the likelihood of MEN1 or MEN2 in the setting of an apparently sporadic single parathyroid adenoma presenting in an individual >30 years of age is low. Furthermore, MEN1 is typically associated with multigland parathyroid disease, whereas primary hyperparathyroidism occurs in a minority of patients with MEN2A and is not a feature of MEN2B. Therefore routine genetic testing for MEN (*MEN1* or *RET*) is not routinely indicated in adults (e.g. >30 years of age) with a solitary parathyroid adenoma in the absence of other relevant clinical features and/or family history. However, *MEN1* genetic testing is indicated for children and young people presenting with primary hyperparathyroidism, as the likelihood of a genetic cause increases in this age group. In addition, genetic testing for MEN may be indicated in adults with recurrent or multi-gland parathyroid disease. Furthermore, in the scenario above, in the absence of a relevant family history, or signs or symptoms of associated endocrine disease, undertaking biochemical or radiological evaluation for MEN-associated tumours would not be indicated.

### Question 2

A 26-year old woman presented with amenorrhoea and reduced libido. Her father and older brother had a clinical diagnosis of MEN1 and carried a known pathogenic *MEN1* mutation. The patient had not undergone genetic testing previously. Clinical examination was normal

Investigations

Serum prolactin 1600 mU/L (<360)

MR scan showed a pituitary microprolactinoma.

**What advice should be given about genetic testing?**

- A. No genetic testing is required as she has almost certainly inherited the *MEN1* mutation from her father
- B. Germline testing of the whole *MEN1* gene should be performed as she may have a different *MEN1* mutation from her father and brother
- C. Germline *MEN1* genetic testing should be performed but limited to determining whether the patient harbours the same mutation as her father and brother
- D. Genetic testing for a panel of genes associated with pituitary tumours including MEN1 should be performed to evaluate for other potential hereditary conditions
- E. Genetic testing for MEN1 should be undertaken, but only if there is evidence of primary hyperparathyroidism

**Answer: C.** All patients at high risk of MEN1 should be offered genetic testing. This includes all first-degree relatives of known mutation carriers, whether they are symptomatic or asymptomatic. For example, here it is possible that the patient has a sporadic pituitary tumour, thereby representing a 'phenocopy' for MEN1. This describes the occurrence of clinical features characteristic of a given genotype (e.g. MEN1) but with a different aetiology (e.g. sporadic tumour). Such phenocopies are estimated to occur in approximately 10% of families with MEN1. In the case above, negative genetic testing will provide the patient reassurance that she has no increased risk of developing further MEN1-associated tumours or passing the mutation on to her children, whereas a positive test will establish the need for continuing MEN1 surveillance.

### Question 3

A 40-year man with MEN1 attended for annual review in the endocrine clinic. He reported some indigestion controlled on treatment. He had a previous history of primary hyperparathyroidism treated with subtotal parathyroidectomy. He was taking omeprazole 20 mg orally daily. Clinical examination was normal.

#### Investigations

Serum corrected calcium 2.40 mmol/L (2.20–2.60)

Plasma gastrin 105 pmol/L (<55)

The remainder of the biochemistry was normal including chromogranin A, glucagon, pancreatic polypeptide.

MRI imaging showed a 0.9cm tumour in the tail of the pancreas not present on a scan 2 years previously.

#### What is the best interpretation and management plan?

- A. The pancreatic abnormality is likely to be a gastrinoma, and the dose of omeprazole should be increased to 20mg twice a day.
- B. He needs immediate referral for surgery as there is a high risk of malignancy associated with the pancreatic neuroendocrine tumour (PNET).
- C. The normal concentrations of chromogranin A, pancreatic polypeptide and glucagon concentrations suggest this is unlikely to be a PNET, and pancreatic imaging should be repeated in 1 year.
- D. The abnormality in the pancreas most likely represents a non-functioning PNET and should be reimaged in a further 3–6 months.
- E. Somatostatin analogue therapy (e.g. octreotide) should be started as the abnormality most likely represents a pancreatic neuroendocrine tumour and may undergo regression.

**Correct Answer: D.** Most gastrinomas in MEN1 are small and occur in the duodenal mucosa. The modest elevation of gastrin in this case may reflect an underlying gastrinoma, but is more likely to be a consequence of proton pump inhibitor therapy, which is associated with hypergastrinaemia (A). Chromogranin A and other gut hormones (e.g. pancreatic polypeptide, glucagon) have a low sensitivity and specificity for detecting pancreatic neuroendocrine tumours (PNETs) (C). In the absence of other symptoms (e.g. hypoglycaemia), the abnormality in the tail of the pancreas is most likely to represent a non-functioning PNET, which is the most common PNET in MEN1. The risk of malignancy is associated with tumour diameter, with surgery typically recommended for tumours >2 cm (B). However, repeat imaging after 3–6 months is recommended as an increase in size over a short interval favours earlier intervention. Somatostatin analogue therapy is typically reserved for patients with locally advanced or metastatic PNETs, or larger tumours unsuitable for resection (E).

.

.