



University of Dundee

Diagnosis of Primary Ciliary Dyskinesia

Goutaki, Myrofora; Shoemark, Amelia

DOI:

[10.1016/j.ccm.2021.11.008](https://doi.org/10.1016/j.ccm.2021.11.008)

Publication date:

2022

Licence:

CC BY-NC-ND

Document Version

Publisher's PDF, also known as Version of record

[Link to publication in Discovery Research Portal](#)

Citation for published version (APA):

Goutaki, M., & Shoemark, A. (2022). Diagnosis of Primary Ciliary Dyskinesia. *Clinics in Chest Medicine*, 43(1), 127-140. <https://doi.org/10.1016/j.ccm.2021.11.008>

General rights

Copyright and moral rights for the publications made accessible in Discovery Research Portal are retained by the authors and/or other copyright owners and it is a condition of accessing publications that users recognise and abide by the legal requirements associated with these rights.

Take down policy

If you believe that this document breaches copyright please contact us providing details, and we will remove access to the work immediately and investigate your claim.

Diagnosis of Primary Ciliary Dyskinesia



Myrofora Goutaki, MSc MD-PhD^{a,b,*}, Amelia Shoemark, BSc PhD^{c,d}

KEYWORDS

• Primary ciliary dyskinesia • Diagnosis • Management • Monitoring • Bronchiectasis

KEY POINTS

- Patients with primary ciliary dyskinesia (PCD) referred for bronchiectasis frequently have clinical problems from other organ systems and require multidisciplinary management.
- Diagnosis of PCD requires a combination of specialized diagnostic tests.
- A comprehensive evaluation of functional and structural information in combination with detailed clinical history remains the cornerstone for accurate referral for PCD diagnosis and further follow-up of PCD.

 Video content accompanies this article at <http://www.chestmed.theclinics.com>.

INTRODUCTION

Primary ciliary dyskinesia (PCD) is a rare multiorgan disease caused by genetic mutations resulting in defects in motile cilia. Because cilia are responsible for clearing the secretions that accumulate in the upper and lower airways, PCD is characterized by impaired mucociliary clearance, which leads to recurrent infections and progressive upper- and lower-respiratory disease. Most patients with PCD will develop bronchiectasis. The clinical phenotype of PCD differs in many cases from the typical patient with bronchiectasis by other causes, and PCD frequently have clinical problems from several organ systems, requiring multidisciplinary management.

In this article, the authors describe the clinical features of PCD and identify which patients should be referred for diagnostic testing. They present an overview of the diagnostic pathway for PCD and discuss why an accurate diagnosis is important.

CLINICAL FEATURES OF PRIMARY CILIARY DYSKINESIA

PCD has an estimated prevalence of 1:10,000 people; however, its true prevalence remains unknown.¹ Many people only get a PCD diagnosis late in adulthood or stay undiagnosed throughout life. PCD is usually inherited as an autosomal recessive condition, and in highly consanguineous populations, a much higher prevalence has been reported.^{2,3}

Approximately 50 disease-causing genes have been identified to date, and despite the large number, they only account for around 70% of PCD.⁴ This genetic heterogeneity leads to variability of cilia morphology and function and therefore to significant phenotypic variability in affected patients. Ciliated epithelia line the upper and lower airways as well as the Eustachian tubes, so respiratory symptoms are common in patients with PCD. Cilia can also be found lining the fallopian tubes in

Funded by: SWISS2021.

^a Institute of Social and Preventive Medicine, University of Bern, Bern, Switzerland; ^b Paediatric Respiratory Medicine, Children's University Hospital of Bern, University of Bern, Bern, Switzerland; ^c Scottish Centre for Respiratory Research, University of Dundee, Dundee, UK; ^d PCD Diagnostic Centre, Paediatric Department, Royal Brompton Hospital, London, UK

* Corresponding author. Institute of Social and Preventive Medicine, University of Bern, Mittelstrasse 43, Bern 3012, Switzerland.

E-mail address: myrofora.goutaki@ispm.unibe.ch

Twitter: [@mgoutaki](https://twitter.com/mgoutaki) (M.G.); [@Shoemelia](https://twitter.com/Shoemelia) (A.S.)

Clin Chest Med 43 (2022) 127–140

<https://doi.org/10.1016/j.ccm.2021.11.008>

0272-5231/22/© 2021 The Author(s). Published by Elsevier Inc. This is an open access article under the CC BY-NC-ND license (<http://creativecommons.org/licenses/by-nc-nd/4.0/>).

women and the efferent duct in men, whereas the sperm flagella has a cilia-like structure.^{5–8} Consequently, male and female infertility has been reported in PCD.⁸ Nodal cilia are responsible for organ left-right asymmetry, and their loss of function leads to situs abnormalities in more than half of the patients.⁹ In rare cases, motile ependymal or nonmotile cilia might also be affected leading to accompanying conditions, such as hydrocephalus, retinitis pigmentosa, or polycystic renal disease.

Evidence describing the prevalence of specific clinical symptoms, their severity, and how they evolve throughout life is sporadic and based mostly on relatively small case studies and retrospective chart reviews.¹⁰ It is however known that PCD may manifest differently according to the patient's age, which is particularly important for identifying suspected patients to refer for diagnosis.

In many patients, PCD presents within hours of birth usually with unspecific symptoms, such as rhinitis and wet cough that may easily go unnoticed. A large proportion of patients presents with late-onset neonatal respiratory distress that can develop days after birth and often requires oxygen and admission to neonatal intensive care.¹¹ Because of low awareness of PCD and its neonatal manifestations, diagnosis is often missed unless PCD neonates present with accompanying abnormalities,¹² such as situs inversus (in approximately 50% of the patients) or other heterotaxic syndromes (in an additional 10%).^{13,14} Around 5% of PCD neonates are born with congenital heart disease, ranging from simpler to more severe defects, which often require urgent intervention.¹⁰

Almost all patients develop chronic wet cough in childhood and are prone to recurrent lower-respiratory-tract infections. Lung function is impaired early on, comparable to cystic fibrosis (CF).¹⁵ In addition to the lower airways, the upper airways and ears are usually affected. Most children with PCD suffer from chronic rhinitis and bilateral otitis media with effusion, which seems to persist longer than in healthy children.^{16,17} In some children, this may lead to hearing impairment and possibly to delays in speech development.¹⁸

Ear problems appear to improve with age, but upper- and lower-respiratory disease persists and usually gets more severe in adulthood.¹⁹ Most adult patients have rhinitis and develop chronic sinusitis with major consequences to their quality of life.¹⁹ Lung disease progresses too, and almost all adults with PCD develop bronchiectasis. In some patients, progressive lung damage might lead to oxygen dependency and need for surgical

management; however, data on severe lung disease and how it affects life expectancy in PCD are sparse.^{20–22} In addition to the increased severity of respiratory symptoms, many male and female young adults with PCD face fertility problems that require specialist counseling as they reach reproductive age and start being concerned with family planning.⁸

Not only does PCD manifest differently throughout life but also it is characterized by important clinical phenotypic variability, because of its significant genetic heterogeneity. In recent years, the discussion about the existence of distinct PCD clinical phenotypes and their association to genotypes has been brought into the spotlight, as it may play a major role in diagnosis and management of patients. So far, several studies have assessed possible associations of PCD disease severity and prognosis with genotype or the corresponding ultrastructural diagnostic phenotype.^{23–25} These phenotype-genotype correlations become more important in informing personalized clinical care decisions and early prevention measures and highlight the importance of accurate diagnosis and genotyping of PCD whenever possible.

WHY SHOULD WE THINK ABOUT PRIMARY CILIARY DYSKINESIA?

As most PCD symptoms are quite nonspecific, many patients, particularly those without laterality defects, remain undiagnosed until adulthood when they are referred to a pulmonology clinic for management after they have developed bronchiectasis.

In an international survey capturing the perspective of patients with PCD on diagnosis, 34% of the respondents reported that they visited their doctor on more than 40 occasions for PCD-related symptoms before PCD was considered a possible diagnosis.²⁶ Particularly, adult participants thought that their current state of health might have been better had they been diagnosed earlier.²⁶ Investigating the cause of bronchiectasis and diagnosing PCD is important not only to satisfy the wish of the patients to resolve their “inconclusive” diagnostic status but also because PCD patients require a disease-specific comprehensive multidisciplinary management approach (**Table 1**).

Management of lung disease focuses on delaying disease progression and improving patients' quality of life. Unfortunately, there is no strong evidence to support most management approaches, and recommendations are usually based on expert experience and extrapolation from other respiratory diseases, such as CF or other causes of

Table 1
Multidisciplinary management and follow-up of patients diagnosed with primary ciliary dyskinesia

Organ System/Area of Care	Clinical Issues	Actions to Consider
Lower airways	<ul style="list-style-type: none"> • Recurrent infections/pulmonary exacerbations • Colonization with pathogens • Impaired lung function • Bronchiectasis 	<ul style="list-style-type: none"> • Regular follow-up by a <i>pulmonologist with expertise in PCD</i> every 3–6 mo • Regular monitoring of lung function (spirometry, other modalities if available) • Regular monitoring of chest imaging (HRCT, MRI) • Regular microbiology cultures and sensitivity test • Antimicrobial treatment of infections, <i>Pseudomonas</i> eradication • Consider antibiotic prophylaxis • Individualized airway clearance regimen (reviewed regularly by a <i>respiratory physiotherapist with expertise in PCD</i>) • Consider inhaled treatments, for example, hypertonic saline • Oxygen supplementation if indicated • Lung surgery (lobectomy, transplantation) if indicated
Upper airways and ears	<ul style="list-style-type: none"> • Chronic rhinosinusitis • Colonization with pathogens • Recurrent episodes of otitis/chronic otitis • Hearing impairment • Delays/issues with speech 	<ul style="list-style-type: none"> • Regular follow-up by an <i>ENT specialist with expertise in PCD</i> minimum annually, more frequently if indicated by symptoms • Regular monitoring with endoscopy/audiometry/tympanometry and further tests if indicated • Sinus CT (at baseline and upon indication) • Regular microbiology culture and sensitivity test • Antimicrobial treatment of infections • Upper-airway clearance regimen/nasal irrigation with saline • Consider nasal steroids (particularly if combined with allergy or in case of polyps) • Hearing aids/speech therapy if indicated • Consider endoscopic sinus surgery if indicated

(continued on next page)

Table 1 (continued)		
Organ System/Area of Care	Clinical Issues	Actions to Consider
Heart	<ul style="list-style-type: none"> • Congenital heart disease (serious types usually discovered at young age, mild issues might remain undiagnosed) 	<ul style="list-style-type: none"> • Echocardiogram/assessment of cardiac involvement • Referral to <i>cardiologist</i> if a defect is discovered and treatment or follow-up as indicated
Fertility	<ul style="list-style-type: none"> • Infertility/subfertility 	<ul style="list-style-type: none"> • Referral to a <i>fertility specialist</i> • Assessment of fertility • Indicated approaches, for example, IVF
Abdomen/kidneys	<ul style="list-style-type: none"> • Situs abnormalities (asplenia, polysplenia) • Renal cysts 	<ul style="list-style-type: none"> • Abdominal imaging at least once in life • Referral to <i>gastroenterologist</i> if a congenital defect is discovered • Referral to <i>nephrologist</i> for renal assessment if indicated
Eyes	<ul style="list-style-type: none"> • Retinitis pigmentosa 	<ul style="list-style-type: none"> • Referral to <i>ophthalmologist</i> if indicated by symptoms or genotype
Nutrition	<ul style="list-style-type: none"> • Possible poor nutrition (usually in younger patients but it might persist) • Possible vitamin D deficiency 	<ul style="list-style-type: none"> • Somatometric assessment at regular intervals • Referral to a <i>nutritionist</i>/encourage healthy diet
Quality of life Mental health	<ul style="list-style-type: none"> • Reduced quality of life • Affected psychological well-being 	<ul style="list-style-type: none"> • Regular monitoring using QOL-PCD • Assessment by a <i>psychologist</i> and if indicated follow-up
General		<ul style="list-style-type: none"> • Recommend regular exercise • Provide or guide patient to educational material about PCD • Encourage contacting PCD support group • Encourage genetic testing/ refer to further diagnostic testing if new or improved techniques are available • <i>Genetic counseling</i> • Immunizations • Avoidance of known risk factors that may further impair health/increase mortality, for example, smoking, frequent exposure to air pollutants

Abbreviations: CT, computed tomography; ENT, ear, nose, throat; IVF, in vitro fertilization; QOL-PCD, quality-of-life instrument for patients with PCD.

bronchiectasis. However, pathophysiology of lung disease in PCD differs importantly and often requires different monitoring and management approaches. Although patients with PCD are often included in bronchiectasis clinical trials as a subsample of the study population, the numbers are usually too small to reach useful conclusions, and there are very few PCD-specific interventional trials to date. Monitoring focuses on prevention and treatment of infections with regular sputum cultures and targeted treatment of new isolated pathogens. The first multicenter randomized clinical trial in patients with PCD showed that prophylactic use of azithromycin resulted in reduction of exacerbations.²⁷ An extremely important part of the management of PCD is airway clearance in order to remove the mucus and minimize lung impairment. There are no studies supporting 1 technique over the others, and current best practice recommends individualized clearance regimens reviewed regularly by professional physiotherapists and extensive education of patients. A combination of clearance techniques with exercise is recommended particularly, as patients with PCD have poor aerobic fitness.²⁸ Lung transplantation might be indicated in the most advanced cases and could be complicated by accompanying laterality defects.

Lung disease progression is traditionally monitored with lung function measured via spirometry; however, spirometric indices, such as FEV1 (forced expiratory volume in 1 second), show great heterogeneity in patients with PCD and might not be the best and most sensitive indicators of disease severity.²⁹ Washout measurements might be more suitable to identify early lung damage, but unfortunately, the equipment is not widely available.^{30,31} Evaluation of structural lung damage is important and does not always correlate with functional damage in PCD.³² High-resolution computed tomography (HRCT) is however used sparingly for follow-up to avoid unnecessary radiation and is reserved for occasions when there are specific clinical concerns. Despite the importance of following structural changes, there is no PCD-specific score evaluating HRCT images.³³ Morphologic and functional MRI has been studied as an alternative with promising results in research but is not widely used in clinical practice. It is important to stress that monitoring of disease progression in PCD requires the use of multiple modalities.³²

In addition to lung management, when a PCD diagnosis is reached, it is important to proceed to a series of additional investigations to clarify the possibility of accompanying complications and comorbidities from other organ systems.

Chronic rhinosinusitis is common among adult patients, who tend to underreport these symptoms, considering them their lifelong normal.¹⁹ Simultaneous management of upper and lower airways is important, and upper-airway clearance with saline irrigation is well tolerated and seems to help symptom control despite the lack of PCD-specific studies.³⁴ In more severe cases, surgical management might be required, for example, endoscopic sinus surgery.³⁵ Although ear infections are less common in adults, conductive hearing loss might be present, and hearing should be monitored.³⁶

Because PCD is a hereditary condition, genetic counseling and in many cases fertility counseling are important, as well as educational resources not only for the patients but also for family members. Because of the need for a specialized multidisciplinary approach and the low awareness of PCD among physicians, diagnosed patients should be referred to specialized PCD centers for follow-up and management to receive optimal care, and if needed, further diagnostic investigations. Diagnosis and good characterization of these patients will help to include them in future PCD-specific clinical trials, to increase the evidence for management of the disease. Most importantly, as small-molecule and gene therapy becomes a more plausible scenario for some diseases, the understanding of genetics and pathophysiology of PCD improves, and the number of genotyped patients increases, studies evaluating molecular treatments are on the horizon. A first trial of this type, the CLEAN-PCD trial, aimed to evaluate the safety and efficacy of the VX-371 compound, an inhaled epithelial sodium channel inhibitor in patients with PCD. The study has been completed, and results are awaited (NCT02871778).

WHEN SHOULD WE THINK ABOUT PRIMARY CILIARY DYSKINESIA

PCD should not be considered only a pediatric disease. Although awareness has increased among adult specialists, an accurate diagnosis is still challenging, particularly for patients who were not diagnosed in childhood. The reported prevalence of PCD in adults with bronchiectasis varies between 1% and 13% in described cohorts; however, most studies had not followed a comprehensive diagnostic approach, and it is likely that PCD was underreported.^{37–39} It is easier to identify patients with strong clinical suspicion, but as PCD is characterized by phenotypic variation, many patients might be missed and never referred for PCD testing. Predictive clinical scores are valuable to

identify patients likely to have PCD.⁴⁰ Unfortunately, access to medical information from the neonatal period is important for available scores so they might be less useful for many adult patients, particularly without laterality defects. Adapted scores might improve screening in this population.⁴¹ Detailed clinical history is important, focusing not only on respiratory symptoms but also on symptoms from other organ systems that patients might tend to underreport or consider less relevant.⁴² Because PCD is a lifelong condition starting at birth, young patients with bronchiectasis who have had CF excluded should be referred for diagnostic testing. They usually have moderate lung function impairment and distinct structural features by HRCT. Upper lobes are usually spared, and the damage is found mainly in the lower and middle lobes, characterized by mucus plugging, peribronchial thickening, and “tree-in-bud” phenomenon.^{33,43} A comprehensive evaluation of functional and structural information in combination with detailed clinical history remains the cornerstone for accurate referral for PCD diagnosis.

ROLE OF NASAL NITRIC OXIDE IN DIAGNOSIS

The first test to consider in an adult with suspected PCD is nasal nitric oxide (NO). When the test is performed according to guidelines with a chemiluminescence analyzer and velum closure, the maneuver has been shown to have a sensitivity of 97.5% and specificity of 96.4% for the condition.⁴⁴

There are 2 evidence-based PCD diagnostic guidelines, and both advocate the use of nasal NO as a test for PCD diagnosis with a cutoff of 77 nL/min recommended to distinguish between PCD and non-PCD.^{44,45} Recently, the combination of nasal NO >77 nL/min with a modified PICADAR score greater than 2 has been described as a good screening strategy for adults with PCD.⁴¹

Importantly, there are an increasing number of patients with PCD and normal nasal NO levels (>77 nL/min) described. Normal NO is often associated with specific genes (RSPH1, DNAH9, FOXJ1) or variants (p.His154Pro variant in *CCDC103*).^{46–49} Individuals with normal NO are more likely to have atypical symptoms and normal or equivocal results in other diagnostic tests too.^{46,48} This makes it more likely that individuals with normal NO will present in adult bronchiectasis clinics with a diagnosis of PCD that has been missed in childhood, similarly to CF with rare CFTR genotypes who have borderline sweat test results.

Conversely, low nasal NO does not always indicate PCD, and there are several conditions in which it can be reduced, for example, in smokers,

some individuals with CF, recent viral infection, or because of nasal obstruction from polyps.⁵⁰

The utility of nasal NO for PCD diagnosis differs according to age. It can be a useful test in adults and older children. However, in babies and younger children, the discriminatory value becomes much less useful.⁵¹ This is thought to be due to the lack of formation of the paranasal sinuses, the main source of nasal NO, until older age. In younger children or those unable to comply with the velum closure protocol requirements for nasal NO measurement (eg, owing to considerable shortness of breath or developmental delay), an alternative tidal breathing technique can be used. Sensitivity and specificity are further reduced using this method.⁵²

There are portable nasal NO analyzers that use electrochemical sensors, and laser-based technology rather than chemiluminescence. These may be available in respiratory clinics for measuring fractional exhaled NO in asthma, and many can be adapted for nasal NO measurements. This increases availability and accessibility of the NO test; however, the sensitivity and specificity for a diagnosis are reduced further with this equipment. It is common for referrals to diagnostic centers be made on the basis of locally performed low NO measured by these analyzers to normalize on repeat testing with a chemiluminescence analyzer.⁵³

FURTHER DIAGNOSTIC TESTING FOR PRIMARY CILIARY DYSKINESIA

The American Thoracic Society and European Respiratory Society (ERS) Guidelines recommend that a diagnosis of PCD be confirmed by the presence of a recognized electron microscopy defect or pathogenic mutations in a known PCD gene.^{44,45} Subtle differences exist between the 2 diagnostic guidelines concerning priority and usage of tests, and these are reviewed elsewhere.⁵⁴ Both guidelines agree that used in isolation ultrastructural analysis or genotyping can only identify ~70% of people known to have PCD, making it difficult to exclude the condition. Therefore, a multitest pathway is recommended. The investigations involved in the multitest pathway are described in the following section with the key concepts and advantages and disadvantages of each investigation. An overview of this pathway is shown in **Table 2**.

Genotyping

There are 50 genes in which pathogenic mutations are known to cause PCD and its associated motile ciliopathies.⁴ Inheritance is usually autosomal

Table 2
Diagnostic algorithm for primary ciliary dyskinesia

Pretesting clinical history	<p>Children</p> <ul style="list-style-type: none"> • Neonatal respiratory distress • Situs anomalies or congenital cardiac defects • Lifelong chronic persistent rhinitis • Chronic middle ear disease with or without hearing loss • Sibling or family member with bronchiectasis or PCD • Hydrocephalus and other features of primary ciliopathies <p>Adults</p> <ul style="list-style-type: none"> • Childhood onset of upper- and lower-respiratory-tract symptoms • Situs anomalies or congenital cardiac defects • Sibling or family member with bronchiectasis or PCD • Male or female infertility with productive cough • Young patients with severe bronchiectasis predominantly in the middle and lower lobes • Hydrocephalus and other features of primary ciliopathies
<i>Nasal nitric oxide</i> This test is unreliable in children <4 y	<ul style="list-style-type: none"> • Performed with a chemiluminescent analyzer and velum closure maneuver • Consistently <77 nL/min suggest <i>further PCD investigations</i> • Consistently >77 nL/min when combined with a low clinical suspicion and/or normal HSVM: <i>PCD highly unlikely</i>
<i>High speed video microscopy (HSVM)</i>	<ul style="list-style-type: none"> • Consistently normal results combined with nasal NO >77 nL/min and/or a low clinical suspicion make a diagnosis of <i>PCD highly unlikely</i> • Abnormal HSVM proceed with <i>further PCD investigations</i> • Because of strong genotype diagnostic phenotype correlations (shown in Table 2), abnormal pattern can help to confirm PCD in patients with class 2 TEM defects or inconclusive genetic results
<i>Immunofluorescence (IF)</i>	<ul style="list-style-type: none"> • Absence of key proteins from the cilia (eg, DNAH5, GAS8) can: • Verify class 2 TEM defects or inconclusive genetic results • Can suggest a likely diagnosis if TEM is not available
<i>Transmission electron microscopy (TEM)</i>	<ul style="list-style-type: none"> • Performed according to international consensus guideline⁷⁷ • Class 1 defects <i>confirm PCD</i> • Class 2 defect suggests PCD: consistent results in other tests are required to confirm the diagnosis <p><i>Normal results don't exclude a diagnosis</i></p>
<i>Genotyping</i>	<ul style="list-style-type: none"> • Performed according to American College of Medical Genetics and Genomics [Richards et al]: • Biallelic pathogenic mutation in a known PCD gene <i>confirm PCD</i> • Biallelic likely pathogenic or variant of uncertain significance in a known PCD gene suggests a diagnosis; consistent results in other tests are required to confirm <p><i>Normal results do not exclude a diagnosis</i></p>
<i>Additional advanced testing modalities</i>	Electron tomography, radiolabeled mucociliary clearance

recessive, but there are some examples of x-linked and dominant inheritance.^{4,49,55} These genes can be categorized into 5 broad functional categories (Table 3).

Despite the large number of PCD genes described, the 4 most common (*DNAH5*, *DNAH11*, *CCDC39* and *CCDC40*) account for greater than 50% of the genetically solved cases in Europe and North America.⁴ Thousands of disease-causing mutations have been described

in these 4 genes. Careful interpretation of genetic results by a person with disease knowledge and further testing with functional tests are often required, especially where variants of uncertain significance are identified. In particular, interpretation in variants in *HYDIN* should be made with caution because of the presence of a pseudogene *HYDIN2* with homology in its sequence.

Clinical genotyping is often achieved with use of a gene panel containing the known PCD genes.

Table 3	
Primary ciliary dyskinesia genes and association with diagnostic phenotype	
Gene	Diagnostic Test Results
<i>Genes coding for structural proteins in the outer dynein arm</i>	
<i>DNAH5, DNAI1, DNAI2, DNAL1, NME8, CCDC114, ARMC4, CCDC151, TTC25</i>	<i>TEM: Class 1 outer dynein arm defect HSVM: Mostly static IF: Absent or misallocated DNAH5</i>
<i>DNAH11</i>	<i>TEM: Normal HSVM: Reduced amplitude and hyperfrequent IF: Absent DNAH11</i>
<i>DNAH9^a</i>	<i>TEM: Partial outer dynein arm defect HSVM: Subtle beat pattern defect IF: DNAH9 absent</i>
<i>Dynein assembly proteins</i>	
<i>DNAAF1 (LRRC50), DNAAF2 (KTU), DNAAF3 (C19ORF51), DNAAF4 (DYX1C1), DNAAF5 (HEATR2), LRRC6, ZMYND10, SPAG1, CFAP298 (C21ORF59), DNAAF6 (PIH1D3), CFAP300 (C11ORF70)</i>	<i>TEM: Outer and inner dynein arm defect HSVM: Immotile IF: Absent DNAH5 and DNALI1</i>
<i>Radial spoke and central complex components</i>	
<i>RSPH9, RSPH4A, RSPH1</i>	<i>TEM: Class 2 central complex defect HSVM: Rotational IF: Absent RSPH9</i>
<i>HYDIN, SPEF2 RSPH3, DNAJB13, STK221, CFAP221</i>	<i>IF: -Absent SPEF2 Other diagnostic tests poorly described or normal</i>
<i>Molecular ruler and dynein regulatory genes</i>	
<i>CCDC39, CCDC40</i>	<i>TEM: Class 1 microtubular disorganization and inner dynein arm defect HSVM: Reduced bending IF: Absent GAS8 and DNALI1</i>
<i>CCDC65 (DRC2), DRC1 (CCDC164), GAS8 (DRC4)</i>	<i>TEM: Class 1 microtubular disorganization HSVM: Subtle defect with pause in beat IF: Absent GAS8</i>
<i>Proteins required for ciliogenesis</i>	
<i>CCNO, MCIDAS, FOXJ1,^a NEK10^a</i>	<i>TEM: Class 2 reduction of multiple motile cilia and mislocalization of basal bodies HSVM & IF: Reduction of multiple motile cilia</i>
<i>Primary ciliopathy associated</i>	
<i>OFD1, RPGR, NHPH</i>	<i>Other diagnostic tests poorly described or normal</i>
<i>Other function</i>	
<i>CCDC103,^a GAS2L2, TTC12</i>	<i>Other diagnostic tests poorly described or normal</i>

^a Cases with normal nasal nitric oxide have been identified.

Because of the continuation of gene discovery, these panels must be updated regularly, and many commercial panels do not contain the full gene set. Alternative options are whole-exome or whole-genome sequencing. This gives the option to return to the sequencing data in light of new gene discovery and search for mutations in new genes in unsolved cases.

Transmission Electron Microscopy

PCD was first described by Afzelius in 1975 by using transmission electron microscopy (TEM) to visualize defects in ciliary ultrastructure. TEM was the gold standard of diagnosis for many years, and it remains the only way to confirm ~30% cases. In the early 1980s, it began to emerge that some individuals with clinical PCD symptoms

had normal ultrastructure when visualized by TEM.⁵⁶ This was confirmed by identification of the gene *DNAH11*, which is associated with normal ultrastructure. *DNAH11* is an outer dynein arm heavy chain responsible for driving motility. Mutations in *DNAH11* are the second most common cause of PCD in Europe and North America. Subsequently, normal or subtle changes in ultrastructure have been associated with several other PCD genes.^{48,57,58} Research innovations based on 3-dimensional visualization of ciliary structure by electron tomography, artificial intelligence, and bioinformatics to average micrographs together can improve the sensitivity of TEM to these subtle defects.^{59,60} The normal ultrastructure as visualized by TEM is shown in **Fig. 1**.

Recently, an international agreement on terminology, adequacy of a diagnostic sample, and a minimum data set to include in a TEM report has been reached.⁶¹ Class 1 defects are diagnostic of PCD and include outer dynein arm defects, outer and inner dynein arm defects, and microtubular disorganization with inner dynein arm defects (see **Fig. 1**). There are additional defects, described as class 2 defects, which can indicate a diagnosis of PCD if seen in association with other diagnostic tests, for example, a corresponding high-speed video microscopy (HSVM) pattern, absence of protein by immunofluorescence, or a mutation in a PCD gene. These class 2 changes include central complex defects; absence of outer, or inner and outer dynein arms in 25% to 50% of cross-sections; mislocalization of basal bodies with few or no cilia; microtubular disorganization with inner dynein arms present. At least 50 axonemes should be inspected in transverse section from many different cells, and more are often required to identify class 2 defects with accuracy.⁶¹ The classifications of defect and strict criteria for analysis aim to reduce complications caused by the presence of secondary ciliary dyskinesia. Secondary ultrastructural defects can overlap with the class 2 diagnostic defects and include compound cilia, loss of central complex, and tubular disorganization. These defects are usually a result of bacterial or viral infection, acute or chronic inflammatory processes, although defects can also be secondary to poor fixation or dehydration technique when processing the sample for TEM. The use of cell culture techniques to grow samples in a sterile environment reduces the presence of secondary defects. If these tools are not available, then repeat sampling from a second site or at a different time can help to tease out the primary versus secondary nature of the ultrastructural changes seen.

High-Speed Video Microscopy

HSVM is a modality by which the pattern and effectiveness of cilia beating can be visualized. The cilia of the airways beat at about 10 to 20 Hz at 37°C in an effective forward stroke followed by a recovery stroke.⁶² The speed and pattern of the beating as well as clearance of overlying mucus and cellular debris can be visualized *ex vivo* by light microscopy (**Videos 1** and **2**). Video images from the microscope recorded at high speed can be played back in slow motion to analyze the ciliary waveform. Relationships between genotype, ultrastructural phenotype, and cilia beat pattern have been identified by HSVM, for example, cilia from patients with absence of dynein arms owing to defects in dynein assembly genes (eg, *DNAAF1-6*) are mostly immotile, whereas those with central complex defects at TEM owing to mutations in genes which code for radial spoke head proteins (*RSPH4a*, *RSPH9*, *RSPH1*) can be seen to rotate.^{63–65} HSVM requires specialist equipment and expertise in interpretation. This is partly due to difficulty in differentiating between ciliary dyskinesia, which is secondary to bacterial infection or epithelial inflammation compared with primary defects. There is currently no standardization or reporting guidelines for the technique, but within centers with extensive expertise, it has been shown to have excellent sensitivity and specificity in the identification of PCD.⁶⁶

HSVM results can be affected if a current or recent upper-respiratory-tract infection has occurred. There can be an absence or reduction in the number of cilia on the respiratory epithelium for analysis. Cilia that are present can appear dyskinetic. To help avoid this situation, it is recommended not to sample the epithelium for diagnostic testing within 4 to 6 weeks of an upper-respiratory-tract infection. As with TEM, HSVM sensitivity can be improved further with the use of primary cell culture techniques to differentiate airway epithelium in a sterile environment before reassessment. Primary PCD defects remain following culture, whereas defects that were secondary to infection or inflammation normalize allowing the diagnosis to be excluded. In the absence of cell culture facilities, a repeat of the original sample can be made.

Immunofluorescence

This technique uses antibodies against key ciliary proteins, which can be fluorescently labeled and visualized by microscopy (see **Fig. 1**). At the time of publication of the ERS diagnostic guidelines, there was no evidence for use of this test, but in

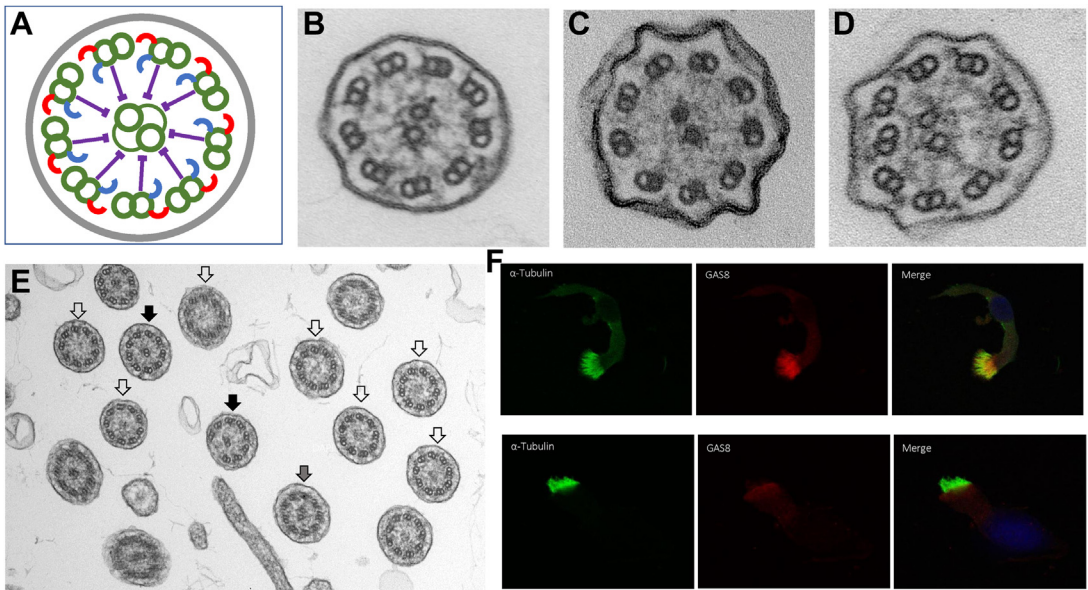


Fig. 1. (A) Normal ciliary ultrastructure including 9 + 2 microtubules (green), outer dynein arms (red), inner dynein arms (blue), and radial spokes (purple). Specific defects in this structure are diagnostic of PCD and include class 1 defects. (B) Outer dynein arm defect. (C) Inner and outer dynein arm defect. (D) Microtubular disorganization and inner dynein arm defect. Further class 2 defects are diagnostic when confirmed with other diagnostic tests. (E) Central complex defect. (open arrows) Absence of the central pair of microtubules. (closed arrows) Translocation of an outer doublet into the center. Some normal cross-sections are also seen. (F) Immunofluorescence testing. Alpha-acetylated tubulin antibody (green) indicates the presence and location of the cilia. GAS8, a dynein regulatory component, is present in the top row (healthy control) and is absent from the cilia in the bottom row (patient with PCD owing to a *CCDC39* defect).

the last few years some studies testing a panel of antibodies for diagnostic sensitivity have been reported.^{67–69} Results are encouraging, showing similar sensitivity and specificity to TEM. Turn-around times and cost of investigation are improved compared with TEM mainly because of a reduced requirement for specialist equipment and expertise in interpretation. These factors make immunofluorescence an attractive option for centers with limited resources. Antibodies to most of the PCD affected structures in the cilium are available and have been tested. Some patients with PCD have normal antibody results,⁷⁰ and standardization of the test is required. Improvements in technology, such as increased availability of superresolution microscopy, may allow the identification of some of these more subtle defects.⁷¹

IMPROVING PRIMARY CILIARY DYSKINESIA DIAGNOSIS: PRIORITIES FOR RESEARCH

Previous research collaborations led to important accomplishments in diagnosis and care of patients with PCD.^{1,27,45,72–74} Current and future clinical and research initiatives aim to improve further

PCD diagnosis. A clinical research collaboration (CRC) supported by the ERS (BEAT-PCD; <https://beat-pcd.squarespace.com/>) aims to advance clinical and translational research in PCD through building on the foundations set by the previous collaborative initiatives and in close collaboration with the ERN-LUNG PCD core (ERN-LUNG; <http://ern-lung.eu>) and the EMBARC ERS CRC on bronchiectasis (<https://www.bronchiectasis.eu/>).^{75,76}

One important priority is to revisit and update the existing diagnostic algorithms, taking into account newer diagnostic evidence aiming to develop new common international diagnostic guidelines for PCD. Standardization of diagnostic test reporting contributes to improved diagnosis; therefore, there is a need to standardize diagnostic results in tests such as HSVM and immunofluorescence, where this is not yet done. An ongoing ERS Task Force aims to develop a technical standard on nasal NO measurement for the diagnosis of PCD. A main aim of BEAT-PCD is to establish an online open database (CiliaVar) registering PCD gene mutations and specific combinations of variants. As clinical genetic testing is increasingly used for PCD, by improving access to PCD variant

information, CiliaVar will contribute to improving PCD diagnosis.⁷⁶

Another area of great importance is to identify key characteristics and clinical outcomes for patients with PCD. Existing test modalities and outcomes used for other respiratory diseases do not appear to be as relevant to assess damage caused by PCD and follow its progression. Not only does this hinder the effective management of patients with PCD but also does not allow the identification of relevant features to distinguish patients who possibly have PCD. PCD-specific clinical scores and identifiable characteristics would help to differentiate PCD from other causes of bronchiectasis in order to refer these patients for further diagnostic testing.

SUMMARY

Diagnosis of PCD depends on a combination of clinical features and a series of diagnostic tests, many of which require expertise and expensive equipment. Despite these difficulties, clinicians caring for patients with bronchiectasis should put effort in identifying patients with suggestive clinical features using the tools available to them and refer them to specialist diagnostic and management centers because these patients require a multidisciplinary management approach.

CLINICS CARE POINTS

- Successful management of patients with primary ciliary dyskinesia requires a multidisciplinary approach with a specialized health care team that will include pulmonologists, ENT specialists, physiotherapists, and specialist nurses. Upon indication or at least for baseline control, the following specialists might also need to be involved in primary ciliary dyskinesia care: cardiologists, fertility specialists, geneticists, nutritionists, psychologists, and in rarer occasions, nephrologists, gastroenterologists, and ophthalmologists.
- Subtle laterality defects, even ones accompanied with mild types of congenital heart disease, might go unnoticed for several years. Therefore, at diagnosis, all patients with primary ciliary dyskinesia should undergo imaging to clarify their presence, as these might complicate management particularly in case a surgical intervention is needed.
- An extensive diagnostic evaluation, including genetic analysis, is recommended for all patients diagnosed with primary ciliary dyskinesia even if the diagnosis is established

with one or 2 tests. Information on genotype and diagnostic phenotype might provide important information for management decisions, as they are often correlated with clinical severity and disease prognosis.

- Primary ciliary dyskinesia is highly heterogeneous, and there might be discordance between lung function and imaging outcomes, so a combination of several modalities is recommended for monitoring of disease progression.
- Despite the lack of clinical trials, an individualized upper- and lower-airway clearance regimen, regularly reviewed by physiotherapists with expertise in primary ciliary dyskinesia, is one of the cornerstones of primary ciliary dyskinesia management.
- Because of the onset of most symptoms in early childhood, patients with primary ciliary dyskinesia might underreport their symptoms and the disease severity, considering them normal. A detailed clinical history at every follow-up visit, using standardized assessment tools, such as the disease-specific FOLLOW-PCD questionnaire, might contribute to a more reliable clinical assessment.
- Prophylactic use of azithromycin has been shown to reduce pulmonary exacerbations in patients with primary ciliary dyskinesia.

DISCLOSURE

The authors have no financial support to disclose. The authors are chairs of the BEAT-PCD clinical research collaboration supported by the European Respiratory Society.

SUPPLEMENTARY DATA

Supplementary data related to this article can be found online at <https://doi.org/10.1016/j.ccm.2021.11.008>.

REFERENCES

1. Kuehni CE, Frischer T, Strippoli M-PF, et al. Factors influencing age at diagnosis of primary ciliary dyskinesia in European children. *Eur Respir J* 2010;36(6):1248–58.
2. O'Callaghan C, Chetcuti P, Moya E. High prevalence of primary ciliary dyskinesia in a British Asian population. *Arch Dis Child* 2010;95(1):51–2.
3. Onoufriadis A, Paff T, Antony D, et al. Splice-site mutations in the axonemal outer dynein arm docking complex gene CCDC114 cause primary ciliary dyskinesia. *Am J Hum Genet* 2013;92(1):88–98.

4. Lucas JS, Davis SD, Omran H, et al. Primary ciliary dyskinesia in the genomics age. *Lancet Respir Med* 2020;8(2):202–16.
5. Aprea I, Nothe-Menchen T, Dougherty GW, et al. Motility of efferent duct cilia aids passage of sperm cells through the male reproductive system. *Mol Hum Reprod* 2021;27(3):gaab009.
6. Raidt J, Werner C, Menchen T, et al. Ciliary function and motor protein composition of human fallopian tubes. *Hum Reprod* 2015;30(12):2871–80.
7. Sironen A, Shoemark A, Patel M, et al. Sperm defects in primary ciliary dyskinesia and related causes of male infertility. *Cell Mol Life Sci* 2020; 77(11):2029–48.
8. Vanaken GJ, Bassinet L, Boon M, et al. Infertility in an adult cohort with primary ciliary dyskinesia: phenotype-gene association. *Eur Respir J* 2017; 50(5):1700314.
9. Hirokawa N, Tanaka Y, Okada Y, et al. Nodal flow and the generation of left-right asymmetry. *Cell* 2006;125(1):33–45.
10. Goutaki M, Meier AB, Halbeisen FS, et al. Clinical manifestations in primary ciliary dyskinesia: systematic review and meta-analysis. *Eur Respir J* 2016; 48(4):1081–95.
11. Mullaney T, Manson D, Kim R, et al. Primary ciliary dyskinesia and neonatal respiratory distress. *Pediatrics* 2014;134(6):1160–6.
12. Goutaki M, Halbeisen FS, Barbato A, et al. Late diagnosis of infants with PCD and neonatal respiratory distress. *J Clin Med* 2020;9(9):2871.
13. Best S, Shoemark A, Rubbo B, et al. Risk factors for situs defects and congenital heart disease in primary ciliary dyskinesia. *Thorax* 2019;74(2):203–5.
14. Shapiro AJ, Davis SD, Ferkol T, et al. Laterality defects other than situs inversus totalis in primary ciliary dyskinesia: insights into situs ambiguus and heterotaxy. *Chest* 2014;146(5):1176–86.
15. Halbeisen FS, Goutaki M, Spycher BD, et al. Lung function in patients with primary ciliary dyskinesia: an iPCD cohort study. *Eur Respir J* 2018;52(2): 1801040.
16. Pruliere-Escabasse V, Coste A, Chauvin P, et al. Otolgic features in children with primary ciliary dyskinesia. *Arch Otolaryngol Head Neck Surg* 2010; 136(11):1121–6.
17. Takeuchi K, Kitano M, Sakaida H, et al. Analysis of otologic features of patients with primary ciliary dyskinesia. *Otol Neurotol* 2017;38(10):e451–6.
18. Kreicher KL, Schopper HK, Naik AN, et al. Hearing loss in children with primary ciliary dyskinesia. *Int J Pediatr Otorhinolaryngol* 2018;104:161–5.
19. Bequignon E, Dupuy L, Zerah-Lancner F, et al. Critical evaluation of sinonasal disease in 64 adults with primary ciliary dyskinesia. *J Clin Med* 2019;8(5):619.
20. Frija-Masson J, Bassinet L, Honore I, et al. Clinical characteristics, functional respiratory decline and follow-up in adult patients with primary ciliary dyskinesia. *Thorax* 2017;72(2):154–60.
21. Noone PG, Leigh MW, Sannuti A, et al. Primary ciliary dyskinesia: diagnostic and phenotypic features. *Am J Respir Crit Care Med* 2004;169(4): 459–67.
22. Shah A, Shoemark A, MacNeill SJ, et al. A longitudinal study characterising a large adult primary ciliary dyskinesia population. *Eur Respir J* 2016;48(2):441–50.
23. Davis SD, Ferkol TW, Rosenfeld M, et al. Clinical features of childhood primary ciliary dyskinesia by genotype and ultrastructural phenotype. *Am J Respir Crit Care Med* 2015;191(3):316–24.
24. Goutaki M, Pedersen ES. Phenotype-genotype associations in primary ciliary dyskinesia: where do we stand? *Eur Respir J* 2021;58(2):2100392.
25. Shoemark A, Rubbo B, Legendre M, et al. Topological data analysis reveals genotype-phenotype relationships in primary ciliary dyskinesia. *Eur Respir J* 2021;58(2):2002359.
26. Behan L, Dunn Galvin A, Rubbo B, et al. Diagnosing primary ciliary dyskinesia: an international patient perspective. *Eur Respir J* 2016;48(4):1096–107.
27. Kobbernagel HE, Buchvald FF, Haarman EG, et al. Efficacy and safety of azithromycin maintenance therapy in primary ciliary dyskinesia (BESTCILIA): a multicentre, double-blind, randomised, placebo-controlled phase 3 trial. *Lancet Respir Med* 2020; 8(5):493–505.
28. Madsen A, Green K, Buchvald F, et al. Aerobic fitness in children and young adults with primary ciliary dyskinesia. *PLoS One* 2013;8(8):e71409.
29. Halbeisen FS, Jose A, de Jong C, et al. Spirometric indices in primary ciliary dyskinesia: systematic review and meta-analysis. *ERJ Open Res* 2019;5(2). 00231-2018.
30. Nyilas S, Schlegteendal A, Yasmine S, et al. Further evidence for an association between LCI and FEV1 in patients with PCD. *Thorax* 2015;70(9):896.
31. Singer F, Schlegteendal A, Nyilas S, et al. Lung clearance index predicts pulmonary exacerbations in individuals with primary ciliary dyskinesia: a multicentre cohort study. *Thorax* 2021;76(7):681–8.
32. Nyilas S, Bauman G, Pusterla O, et al. Structural and functional lung impairment in primary ciliary dyskinesia. assessment with magnetic resonance imaging and multiple breath washout in comparison to spirometry. *Ann Am Thorac Soc* 2018;15(12):1434–42.
33. Robinson P, Morgan L. Bronchiectasis in PCD looks different to CF on CT scan. *Multidiscip Respir Med* 2018;13(Suppl 1):24.
34. Bequignon E, Dupuy L, Escabasse V, et al. Follow-up and management of chronic rhinosinusitis in adults with primary ciliary dyskinesia: review and experience of our reference centers. *J Clin Med* 2019;8(9):1495.

35. Alanin MC, Aanaes K, Hoiby N, et al. Sinus surgery can improve quality of life, lung infections, and lung function in patients with primary ciliary dyskinesia. *Int Forum Allergy Rhinol* 2017;7(3):240–7.
36. Piatti G, De Santi MM, Torretta S, et al. Cilia and ear. *Ann Otol Rhinol Laryngol* 2017;126(4):322–7.
37. Contarini M, Shoemark A, Rademacher J, et al. Why, when and how to investigate primary ciliary dyskinesia in adult patients with bronchiectasis. *Multidiscip Respir Med* 2018;13(Suppl 1):26.
38. Lonni S, Chalmers JD, Goeminne PC, et al. Etiology of non-cystic fibrosis bronchiectasis in adults and its correlation to disease severity. *Ann Am Thorac Soc* 2015;12(12):1764–70.
39. Shoemark A, Ozerovitch L, Wilson R. Aetiology in adult patients with bronchiectasis. *Respir Med* 2007;101(6):1163–70.
40. Behan L, Dimitrov BD, Kuehni CE, et al. PICADAR: a diagnostic predictive tool for primary ciliary dyskinesia. *Eur Respir J* 2016;47(4):1103–12.
41. Rademacher J, Buck A, Schwerk N, et al. Nasal nitric oxide measurement and a modified PICADAR score for the screening of primary ciliary dyskinesia in adults with bronchiectasis. *Pneumologie* 2017;71(8):543–8.
42. Goutaki M, Papon JF, Boon M, et al. Standardised clinical data from patients with primary ciliary dyskinesia: follow-PCD. *ERJ Open Res* 2020;6(1). 00237-2019.
43. Kennedy MP, Noone PG, Leigh MW, et al. High-resolution CT of patients with primary ciliary dyskinesia. *AJR Am J Roentgenol* 2007;188(5):1232–8.
44. Shapiro AJ, Davis SD, Polineni D, et al. Diagnosis of primary ciliary dyskinesia. An official American Thoracic Society clinical practice guideline. *Am J Respir Crit Care Med* 2018;197(12):e24–39.
45. Lucas JS, Barbato A, Collins SA, et al. European Respiratory Society guidelines for the diagnosis of primary ciliary dyskinesia. *Eur Respir J* 2017;49(1):1601090.
46. Fassad MR, Shoemark A, Legendre M, et al. Mutations in outer dynein arm heavy chain DNAH9 cause motile cilia defects and situs inversus. *Am J Hum Genet* 2018;103(6):984–94.
47. Knowles MR, Ostrowski LE, Leigh MW, et al. Mutations in RSPH1 cause primary ciliary dyskinesia with a unique clinical and ciliary phenotype. *Am J Respir Crit Care Med* 2014;189(6):707–17.
48. Shoemark A, Moya E, Hirst RA, et al. High prevalence of CCDC103 p.His154Pro mutation causing primary ciliary dyskinesia disrupts protein oligomerisation and is associated with normal diagnostic investigations. *Thorax* 2018;73(2):157–66.
49. Wallmeier J, Frank D, Shoemark A, et al. De novo mutations in FOXJ1 result in a motile ciliopathy with hydrocephalus and randomization of left/right body asymmetry. *Am J Hum Genet* 2019;105(5):1030–9.
50. Walker WT, Jackson CL, Lackie PM, et al. Nitric oxide in primary ciliary dyskinesia. *Eur Respir J* 2012;40(4):1024–32.
51. Marthin JK, Philipsen MC, Rosthøj S, et al. Infant nasal nitric oxide over time: natural evolution and impact of respiratory tract infection. *Eur Respir J* 2018;51(6):1702503.
52. Marthin JK, Nielsen KG. Choice of nasal nitric oxide technique as first-line test for primary ciliary dyskinesia. *Eur Respir J* 2011;37(3):559–65.
53. Harris A, Bhullar E, Gove K, et al. Validation of a portable nitric oxide analyzer for screening in primary ciliary dyskinesias. *BMC Pulm Med* 2014;14:18.
54. Shoemark A, Dell S, Shapiro A, et al. ERS and ATS diagnostic guidelines for primary ciliary dyskinesia: similarities and differences in approach to diagnosis. *Eur Respir J* 2019;54(3):1901066.
55. Olcese C, Patel MP, Shoemark A, et al. X-linked primary ciliary dyskinesia due to mutations in the cytoplasmic axonemal dynein assembly factor PIH1D3. *Nat Commun* 2017;8:14279.
56. Greenstone MA, Dewar A, Cole PJ. Ciliary dyskinesia with normal ultrastructure. *Thorax* 1983;38(11):875–6.
57. Boon M, Smits A, Cuppens H, et al. Primary ciliary dyskinesia: critical evaluation of clinical symptoms and diagnosis in patients with normal and abnormal ultrastructure. *Orphanet J Rare Dis* 2014;9:11.
58. Olbrich H, Schmidts M, Werner C, et al. Recessive HYDIN mutations cause primary ciliary dyskinesia without randomization of left-right body asymmetry. *Am J Hum Genet* 2012;91(4):672–84.
59. Shoemark A, Burgoyne T, Kwan R, et al. Primary ciliary dyskinesia with normal ultrastructure: three-dimensional tomography detects absence of DNAH11. *Eur Respir J* 2018;51(2):1701809.
60. Shoemark A, Pinto AL, Patel MP, et al. PCD detect: enhancing ciliary features through image averaging and classification. *Am J Physiol Lung Cell Mol Physiol* 2020;319(6):L1048–60.
61. Shoemark A, Boon M, Brochhausen C, et al. International consensus guideline for reporting transmission electron microscopy results in the diagnosis of primary ciliary dyskinesia (BEAT PCD TEM criteria). *Eur Respir J* 2020;55(4):1900725.
62. Chilvers MA, Rutman A, O’Callaghan C. Functional analysis of cilia and ciliated epithelial ultrastructure in healthy children and young adults. *Thorax* 2003;58(4):333–8.
63. Blanchon S, Legendre M, Bottier M, et al. Deep phenotyping, including quantitative ciliary beating parameters, and extensive genotyping in primary ciliary dyskinesia. *J Med Genet* 2020;57(4):237–44.

64. Castleman VH, Romio L, Chodhari R, et al. Mutations in radial spoke head protein genes RSPH9 and RSPH4A cause primary ciliary dyskinesia with central-microtubular-pair abnormalities. *Am J Hum Genet* 2009;84(2):197–209.
65. Chilvers MA, Rutman A, O'Callaghan C. Ciliary beat pattern is associated with specific ultrastructural defects in primary ciliary dyskinesia. *J Allergy Clin Immunol* 2003;112(3):518–24.
66. Rubbo B, Shoemark A, Jackson CL, et al. Accuracy of high-speed video analysis to diagnose primary ciliary dyskinesia. *Chest* 2019;155(5):1008–17.
67. Baz-Redon N, Rovira-Amigo S, Fernandez-Cancio M, et al. Immunofluorescence analysis as a diagnostic tool in a Spanish cohort of patients with suspected primary ciliary dyskinesia. *J Clin Med* 2020;9(11):3603.
68. Frommer A, Hjeij R, Loges NT, et al. Immunofluorescence analysis and diagnosis of primary ciliary dyskinesia with radial spoke defects. *Am J Respir Cell Mol Biol* 2015;53(4):563–73.
69. Shoemark A, Frost E, Dixon M, et al. Accuracy of immunofluorescence in the diagnosis of primary ciliary dyskinesia. *Am J Respir Crit Care Med* 2017;196(1):94–101.
70. Dougherty GW, Loges NT, Klinkenbusch JA, et al. DNAH11 localization in the proximal region of respiratory cilia defines distinct outer dynein arm complexes. *Am J Respir Cell Mol Biol* 2016;55(2):213–24.
71. Liu Z, Nguyen QPH, Guan Q, et al. A quantitative super-resolution imaging toolbox for diagnosis of motile ciliopathies. *Sci Transl Med* 2020;12(535):eaay0071.
72. Goutaki M, Maurer E, Halbeisen FS, et al. The International Primary Ciliary Dyskinesia Cohort (iPCD Cohort): methods and first results. *Eur Respir J* 2017;49(1):1601181.
73. Lucas JS, Behan L, Dunn Galvin A, et al. A quality-of-life measure for adults with primary ciliary dyskinesia: QOL-PCD. *Eur Respir J* 2015;46(2):375–83.
74. Werner C, Lablans M, Ataian M, et al. An international registry for primary ciliary dyskinesia. *Eur Respir J* 2016;47(3):849–59.
75. Aliberti S, Polverino E, Chalmers JD, et al. The European Multicentre Bronchiectasis Audit and Research Collaboration (EMBARC) ERS Clinical Research Collaboration. *Eur Respir J* 2018;52(5):1802074.
76. Goutaki M, Crowley S, Dehlink E, et al. The BEAT-PCD (better experimental approaches to treat primary ciliary dyskinesia) Clinical Research Collaboration. *Eur Respir J* 2021;57(2):2004601.
77. Richards, et al. Standards and guidelines for the interpretation of sequence variants: a joint consensus recommendation of the American College of Medical Genetics and Genomics and the Association for Molecular Pathology. *Genet Med* 2015 May;17(5):405–24.