



University of Dundee

First step for computer assisted evaluation of qualitative supersonic shear wave elastography characteristics in breast tissue.

Skerl, Katrin; Vinnicombe, Sarah; McKenna, Stephen; Thomson, Kim; Evans, Andrew

Published in:
2016 IEEE 13th International Symposium on Biomedical Imaging

DOI:
[10.1109/ISBI.2016.7493312](https://doi.org/10.1109/ISBI.2016.7493312)

Publication date:
2016

Licence:
No Licence / Unknown

Document Version
Peer reviewed version

[Link to publication in Discovery Research Portal](#)

Citation for published version (APA):
Skerl, K., Vinnicombe, S., McKenna, S., Thomson, K., & Evans, A. (2016). First step for computer assisted evaluation of qualitative supersonic shear wave elastography characteristics in breast tissue. In *2016 IEEE 13th International Symposium on Biomedical Imaging: From Nano to Macro, ISBI 2016 - Proceedings* (Vol. 2016-June, pp. 481-484). IEEE. <https://doi.org/10.1109/ISBI.2016.7493312>

General rights

Copyright and moral rights for the publications made accessible in Discovery Research Portal are retained by the authors and/or other copyright owners and it is a condition of accessing publications that users recognise and abide by the legal requirements associated with these rights.

Take down policy

If you believe that this document breaches copyright please contact us providing details, and we will remove access to the work immediately and investigate your claim.

FIRST STEP FOR COMPUTER ASSISTED EVALUATION OF QUALITATIVE SUPERSONIC SHEAR WAVE ELASTOGRAPHY CHARACTERISTICS IN BREAST TISSUE

Katrin Skerl^{*}, Sarah Vinnicombe^{*†}, Stephen McKenna[‡], Kim Thomson[†], Andrew Evans^{*†}

^{*} University of Dundee, Ninewells Hospital & Medical School, Mailbox 4, Dundee, DD1 9SY, UK

[‡] School of Science and Engineering (Computing), University of Dundee, Dundee, DD1 4HN, UK

[†] Breast Imaging Department, Ninewells Hospital, Dundee, DD1 9SY, UK

ABSTRACT

The addition of shear wave elastography (SWE) imaging to standard B-mode ultrasound assessment supports the differential diagnosis of solid breast lesions. One way to assess SWE images is qualitative evaluation of the stiffness pattern according to the Tozaki classification. Until now this qualitative assessment has only been possible manually and so has low reproducibility and high inter-observer variability. Thus, this work aims to investigate the feasibility of automatic assessment of Tozaki categories. SWE images of 41 solid breast lesions (9 benign, 32 malignant) were assessed manually by a radiologist and automatically. The results were compared to the histology of the lesions. The diagnostic performance of the automatic assessment is similar to the manual assessment. The algorithm introduced in this work demonstrates the ability to automatically assess qualitative SWE features, given segmented lesions, according to the Tozaki classification.

Index Terms— Computer assisted diagnosis, ultrasound, elastography, breast, cancer

1. INTRODUCTION

Supersonic shear wave elastography (SWE) imaging was introduced by Bercoff et al. in 2004 [1] and has been in clinical application in breast imaging since 2009 [2]. This technique visualises the elasticity of the tissue represented by Young's Modulus as a colour map overlaying the standard ultrasound grey-scale image (Fig. 1). Tozaki and Fukuma [3] evaluated the stiffness pattern and introduced four categories: 1 - homogenous blue, 2 - vertical stripes of stiffness, 3 - stiffness in the tissue adjacent to the lesion, 4 - stiffness inside the lesion. Categories 1 and 2 suggest benign lesions whereas categories 3 and 4 suggest malignancy. However, until now it has only been possible to assess the qualitative pattern manually. This results in a high inter-observer variation and low reproducibility. Hence, this paper introduces an algorithm enabling

We want to thank Prof. Sandy Cochran for his support during this project. This project is part of a PhD studentship which is funded by the Engineering and Physical Science Research Council (EPSRC) and SuperSonic Imagine.

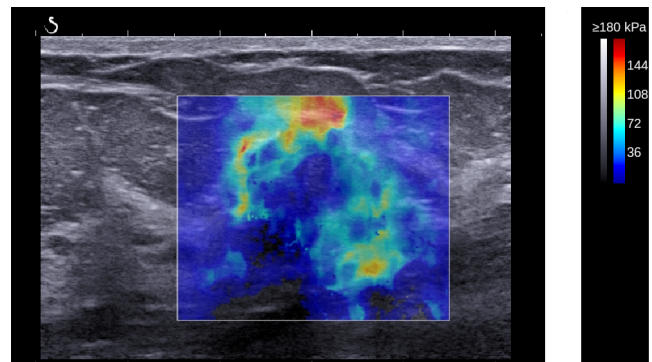


Fig. 1. SWE image of a malignant solid breast lesion. The elasticity values are represented as a colour map overlaying the grey-scale B-mode ultrasound image

automatic pattern evaluation of stiffness on SWE images according to the above summarised Tozaki classifications.

2. MATERIALS & METHODS

2.1. Study-group

The retrospective study-group comprised 41 solid breast lesions in 40 patients (age range 24-90 years, mean 62.5 years) attending routine breast imaging in our clinic between September 2012 and April 2013. Four images, two in each of two orthogonal planes, were obtained for each patient. Symptomatic and screen detected lesions were included. Only lesions undergoing core-biopsy or surgical excision were included. No further exclusion criteria were applied. Ethical approval by the National Research Ethics Service guidance was not necessary [4]. Written informed consent for the use of images in our research was obtained, as is standard procedure in our clinic.

2.2. Ultrasound device

All images were acquired using the Aixplorer ultrasound imaging system (SuperSonic Imagine, Aix en Provence,

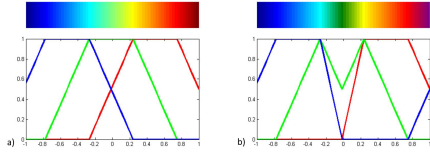


Fig. 2. a) Standard “jet” colour representation as used by image processing software such as MATLAB. b) Adjusted colour representation for 50% opacity [5].

France). The ultrasound probe had a frequency range 4 - 15 MHz with axial resolution 0.3 - 0.5 mm and lateral resolution 0.3 - 0.6 mm. The same probe was used to obtain the B-mode and SWE images. The opacity of the colour map was set to 50% with an elasticity range of 0 - 180 kPa, blue - red.

2.3. Image evaluation

A radiologist with more than 20 years of experience in breast imaging and more than 5 years experience in SWE imaging assessed all images of the study-group accordingly to the Tozaki classification.

The automatic image evaluation was performed using MATLAB (MathWorks, Natick, Massachusetts, USA). In the first step the colour coded SWE images were converted back into their elasticity values using the approach as introduced by Skerl et al. [5]. Each colour pixel was converted into its elasticity value according to the colour map displayed in Fig. 2. Thus, an elasticity matrix was created.

To evaluate if the stiffness is inside or outside the lesion (Tozaki 3 and 4), the lesion needs to be segmented. This was achieved using the algorithm as introduced by Xian et al. [6]. Unfortunately this automatic segmentation was unsuccessful for lesions with a heterogeneous echo pattern or significant posterior shadowing (29 out of the 41 lesions). Hence, the automatically found lesion was displayed for manual approval and if incorrect the boundary of the lesion was drawn manually by the observer.

Finally the Tozaki criteria were applied to the lesion. Tozaki pattern 1 describes a homogeneous blue image (Fig. 3a), i.e. all elasticity values under 71 kPa according to the defined colourmap (Fig. 2 [5]). However, single pixels of higher elasticity might be included in the image. Hence, only objects larger than 5x5 mm were evaluated. The ad-hoc threshold of 5x5 mm was chosen after discussion with the radiologist to reflect clinical scenarios, as lesions smaller than 5 mm are difficult to evaluate. If no object is stiffer than 71 kPa, the SWE image is homogeneous blue.

Pattern 2 describes one or more vertical stripes of stiffness extending from the top of the image (Fig. 3b). We defined a stripe further to have an aspect ratio of at least 1.5. So first the elasticity matrix is converted into a binary image segmenting stiffer parts. Then all objects comprised in the image are




Fig. 3. a) Homogeneous blue lesion (Tozaki 1). b) The SWE image comprises a vertical stripe of stiffness (Tozaki 2).

segmented individually and the dimensions of each object are evaluated. If the object’s aspect ratio is at least 1.5 and the object originates from the skin, i.e. the top of the SWE image, Tozaki pattern 2 is present in the SWE image.

Pattern 3 describes stiffness in the tissue adjacent to the lesion (Fig. 4a). Thus the binary image comprising the segmented lesion (Fig. 4b) is inverted and multiplied with the elasticity matrix (Fig. 4c). The received image is thresholded to segment stiffer areas (threshold value 0.5 of the maximum stiffness present). If an area of stiffness larger than 5x5 mm is comprised in the tissue adjacent to the lesion, pattern 3 is present.

Pattern 4 on the other hand describes stiffness inside the lesion (Fig. 5a). So the elasticity matrix is multiplied with the binary image comprising the segmented lesion (Fig. 5b). However, often the adjacent stiffness (pattern 3) spreads into the lesion. Thus, the boundary of the lesion should be excluded. To segment the boundary area, the boundary of the lesion is detected and dilated into a 10 pixel wide line (Fig. 5c). The image is then inverted and multiplied with the elasticity matrix (Fig. 5d). The elasticity matrix is thresholded to segment stiffer parts (threshold value 0.5 of the maximum stiffness present). If stiffness inside the lesion covers at least 1/3 of the area of the lesion, the lesion is rated as a pattern 4 lesion.

Patterns 1 and 2 were rated as benign lesions whereas patterns 3 and 4 were rated as malignant lesions.

The pathological results from core-biopsy or surgical excision were the gold standard.

3. RESULTS

The study-group comprised 9 benign and 32 malignant lesions. The distribution of the lesions over the various Tozaki patterns assessed by the manual observer and the algorithm is shown in Table 1. Table 2 shows the sensitivity, specificity and diagnostic accuracy of the automatic and the manual assessment. No significant difference in diagnostic performance was seen between the manual and the automatic assessment (Fisher’s exact test, SISA, Quantitative Skills, Hilversum, Netherlands).



Fig. 4. a) Stiffness is present in the tissue adjacent to the lesion (Tozaki 3). b) Binary image of the segmented lesion. c) The binary image is inverted and multiplied with the elasticity matrix to segment the part outside the lesion.




Fig. 5. a) Stiffness inside the lesion represents pattern 4. b) Binary image of the segmented lesion. c) The boundary of the lesion is found and dilated into a 10 pixel wide line. d) The boundary image is subtracted from the segmented lesion and then the SWE image is multiplied so only the SWE image inside the lesion remains.

4. DISCUSSION

| Assessment | Pattern 1 | Pattern 2 | Pattern 3 | Pattern 4 |
|------------|-----------|-----------|-----------|-----------|
| Manual | 4 (3/1) | 9 (3/6) | 23 (1/22) | 5 (2/3) |
| Automatic | 7 (3/4) | 3 (1/2) | 27 (4/23) | 4 (1/3) |

Numbers in brackets are the numbers of benign/malignant lesions

Table 1. Distribution of the four patterns over the study-group.

| Assessment | Se [%] | Sp [%] | DA [%] |
|------------|--------|--------|--------|
| Manual | 78 | 67 | 76 |
| Automatic | 81 | 44 | 73 |
| P-value | 1.0 | 0.7 | 1.0 |

Se - Sensitivity, Sp - Specificity, DA - Diagnostic accuracy

Table 2. Diagnostic performance of the manual and the automatic assessment.

In this paper we demonstrate the feasibility of CAD of solid breast lesion's appearance on 2D supersonic SWE according to the Tozaki classification [3]. This has the potential to increase reproducibility and reduces inter-observer variability. No significant difference ($p > 0.05$) was observed in the diagnostic performance of the algorithm and the manual assessment. However, numbers were limited in this study which might bias the results.

The evaluated study-group comprised only a very low number of Tozaki 2 lesions whereas the majority were Tozaki 3 lesions. This too might have resulted in bias. However, if a consecutive study-group is used, a majority of Tozaki 3 lesions is expected at our institute as we generally see a high number of malignant cases. Nevertheless, the algorithm will be applied to a larger study-group in our next step to verify the results. The identification of the stripe pattern (Tozaki 2) might need improvement and future work will address this. Although, the algorithm developed during this project has potential of improvement and a lower specificity than the manual assessment (not significant, $p > 0.05$), its diagnostic performance is promising. However, only three out of the nine manual Tozaki 2 lesions were recognised correctly. In this work a stripe is assumed to have an aspect ratio of at least 1.5 to exclude malignant lesions which have also sometimes an aspect ratio higher than 1.0. Hence, the correct identification of Tozaki 2 should be improved in the future.

The thresholds used during this work were ad-hoc according to the discussion with the experienced radiologist. Hence, the

thresholds should be verified by the application to a larger study-group in the future.

Lesion segmentation is one of the basic requirements to enable the automatic pattern evaluation. During this work, the algorithm introduced by Xian et al. was used [6]. However, this algorithm did not correctly segment lesions with a heterogeneous echo pattern or significant posterior shadowing. Thus, manual evaluation by an observer was necessary with occasional manual correction of lesion boundaries. So full automatic pattern evaluation was not possible during this work. However, this feasibility study aims to investigate CAD according to Tozaki and not lesion segmentation. Nevertheless, automatic lesion segmentation should be addressed in future. Furthermore, as both categories Tozaki 3 and 4 suggest malignancy, one can argue that lesion segmentation is not required for the benign/malignant differentiation. However, lesion segmentation might support the correct classification of Tozaki 2. Additionally, this might be of interest for a future combination with other SWE and ultrasound characteristics such as the quantitative SWE assessment.

To the best of our knowledge, no other approach for an automatic Tozaki assessment is yet in existence. Nevertheless, quantification of stiffness heterogeneity [7] and CAD of SWE quantitative features [5, 8] have been studied. Combining quantitative and qualitative SWE features improves the diagnostic performance [9]. This may lead to a diagnostic accuracy as high as 98% if combined with the evaluation of the lesions grey-scale ultrasound appearance [10]. Hence, an extension of the algorithm introduced in this paper to include quantitative SWE and BI-RADS assessment might be of interest in the future.

5. CONCLUSION

This feasibility study shows that automatic assessment of qualitative characteristics of supersonic SWE images according to the Tozaki classification is possible, given segmented lesions. However, further work should be performed to improve this algorithm.

6. REFERENCES

- [1] Jérémy Bercoff, Mickael Tanter, and Mathias Fink, “Supersonic shear imaging: a new technique for soft tissue elasticity mapping,” *IEEE Transactions On Ultrasonics, Ferroelectrics, And Frequency Control*, vol. 51, no. 4, pp. 396–409, 2004.
- [2] Wendie A. Berg, David O. Cosgrove, Caroline J. Doré, Fritz K. W. Schäfer, William E. Svensson, Regina J. Hooley, Ralf Ohlinger, Ellen B. Mendelson, Catherine Balu-Maestro, Martina Locatelli, Christophe Tourasse, Barbara C. Cavanaugh, Valrie Juhan, A. Thomas Stavros, Anne Tardivon, Joel Gay, Jean-Pierre Henry, and Claude Cohen-Bacrie, “Shear-wave elastography improves the specificity of breast us: the be1 multinational study of 939 masses,” *Radiology*, vol. 262, no. 2, pp. 435–449, 2012.
- [3] Mitsuhiro Tozaki and Eisuke Fukuma, “Pattern classification of shearwave elastography images for differential diagnosis between benign and malignant solid breast masses,” *Acta Radiologica (Stockholm, Sweden: 1987)*, vol. 52, no. 10, pp. 1069–1075, 2011.
- [4] National Research Ethics Service, “Approval for medical devices research: Guidance for researchers, manufacturers,” 2008, Version 2 London: National Patient Safety Agency; available at www.hra.nhs.uk; accessed 08-05-2014.
- [5] Katrin Skerl, Sandy Cochran, and Andrew Evans, “Automatic estimation of elasticity parameters in breast tissue,” *Proc. SPIE*, vol. 9040, pp. 90401G–90401G–8, 2014.
- [6] Min Xian, Yingtao Zhang, and H.D. Cheng, “Fully automatic segmentation of breast ultrasound images based on breast characteristics in space and frequency domains,” *Pattern Recognition*, vol. 48, no. 2, pp. 485–497, 2015.
- [7] Qi Zhang, Yang Xiao, Shuai Chen, Congzhi Wang, and Hairong Zheng, “Quantification of elastic heterogeneity using contourlet-based texture analysis in shear-wave elastography for breast tumor classification,” *Ultrasound in medicine & biology*, vol. 41, no. 2, pp. 588–600, 2015.
- [8] Yang Xiao, Jie Zeng, Lili Niu, Qingjing Zeng, Tao Wu, Congzhi Wang, Rongqin Zheng, and Hairong Zheng, “Computer-aided diagnosis based on quantitative elastographic features with supersonic shear wave imaging,” *Ultrasound In Medicine & Biology*, vol. 40, no. 2, pp. 275–286, 2014.
- [9] M Elseedawy, P Whelehan, S Vinnicombe, D McLean, K Thomson, and A Evans, “Pb.44. do qualitative patterns of stiffness help differentiate benign from malignant breast masses of similar stiffness during shear wave elastography?,” *Breast Cancer Research*, vol. 16, no. Suppl 1, pp. P49, 2014.
- [10] JianQiao Zhou, WeiWei Zhan, Cai Chang, XiaoXiao Zhang, Yi Jia, YiJie Dong, Chun Zhou, Jing Sun, and Edward G Grant, “Breast lesions: Evaluation with shear wave elastography, with special emphasis on the stiff rim sign,” *Radiology*, vol. 272, no. 1, pp. 63–72, 2014.