



University of Dundee

Managing carious lesions

Innes, N.P.T.; Frencken, J.E.; Bjørndal, L.; Maltz, M.; Manton, D.J.; Ricketts, D.

Published in:

Advances in Dental Research: an E-Supplement to Journal of Dental Research

DOI:

[10.1177/0022034516639276](https://doi.org/10.1177/0022034516639276)

Publication date:

2016

Document Version

Peer reviewed version

[Link to publication in Discovery Research Portal](#)

Citation for published version (APA):

Innes, N. P. T., Frencken, J. E., Bjørndal, L., Maltz, M., Manton, D. J., Ricketts, D., Van Landuyt, K., Banerjee, A., Campus, G., Doméjean, S., Fontana, M., Leal, S., Lo, E., Machiulskiene, V., Schulte, A., Splieth, C., Zandona, A., & Schwendicke, F. (2016). Managing carious lesions: consensus recommendations on terminology. *Advances in Dental Research: an E-Supplement to Journal of Dental Research*, 28(2), 49-57. <https://doi.org/10.1177/0022034516639276>

General rights

Copyright and moral rights for the publications made accessible in Discovery Research Portal are retained by the authors and/or other copyright owners and it is a condition of accessing publications that users recognise and abide by the legal requirements associated with these rights.

Take down policy

If you believe that this document breaches copyright please contact us providing details, and we will remove access to the work immediately and investigate your claim.

1 **Managing carious lesions: Consensus recommendations on terminology**

2 Nicola P.T. Innes¹, Jo E. Frencken², Lars Bjørndal³, Marisa Maltz⁴, David J. Manton⁵, David
3 Ricketts⁶, Kirsten Van Landuyt⁷, Avijit Banerjee⁸, Guglielmo Campus⁹, Sophie Doméjean¹⁰,
4 Margherita Fontana¹¹, Soraya Leal¹², Edward Lo¹³, Vita Machiulskiene¹⁴, Andreas Schulte¹⁵,
5 Christian Splieth¹⁶, Andrea Zandona¹⁷ Falk Schwendicke¹⁸

6

7 ¹ Paediatric Dentistry, Dundee Dental Hospital and School, University of Dundee, Dundee,
8 UK

9 ² Department of Oral Function and Prosthetic Dentistry, College of Dental Sciences,
10 Radboud University Medical Centre, Nijmegen, The Netherlands

11 ³ Department of Cariology & Endodontics, Faculty of Health and Medical Sciences,
12 University of Copenhagen, Denmark

13 ⁴ Department of Preventive and Social Dentistry, Faculty of Odontology, Federal University
14 of Rio Grande do Sul, Brazil

15 ⁵ Melbourne Dental School, University of Melbourne, Australia

16 ⁶ Operative Dentistry, Fixed Prosthodontics and Endodontology, Dundee Dental Hospital
17 and School, University of Dundee, Dundee, UK

18 ⁷ KULeuven BIOMAT, Department of Oral Health Sciences, University of Leuven & Dentistry
19 University Hospitals Leuven, Kapucijnenvoer 7, 3000 Leuven, Belgium;

20 ⁸ Conservative & MI Dentistry, King's College London Dental Institute at Guy's Hospital,
21 King's Health Partners, London, UK.

22 ⁹ Department of Surgery, Microsurgery and Medicine Sciences, School of Dentistry,
23 University of Sassari, Italy, WHO Collaborating Centre for Epidemiology and Community
24 Dentistry, University of Milan, Italy

25 ¹⁰ CHU Clermont-Ferrand, Service d'Odontologie, Hôtel-Dieu, F-63001; Univ Clermont1,
26 UFR d'Odontologie; Centre de Recherche en Odontologie Clinique EA 4847, F-63000
27 Clermont-Ferrand, France.

28 ¹¹ Department of Cariology, Restorative Sciences and Endodontics, School of Dentistry,
29 University of Michigan; Ann Arbor, Michigan, USA

30 ¹² Department of Dentistry, Faculty of Health Sciences, University of Brasília, Brazil

31 ¹³ Faculty of Dentistry, University of Hong Kong

32 ¹⁴ Department of Dental and Oral Pathology, Faculty of Odontology, Lithuanian University of
33 Health Sciences, Kaunas, Lithuania

34 ¹⁵ Department of Special Care Dentistry, Faculty of Health, University of Witten/Herdecke,
35 Witten, Germany

36 ¹⁶ Preventive & Pediatric Dentistry, University of Greifswald, Greifswald, Germany

37 ¹⁷ Department of Operative Dentistry, University of North Carolina at Chapel Hill School of
38 Dentistry, Chapel Hill, North Carolina, USA

39 ¹⁸ Department of Operative and Preventive Dentistry, Charité - Universitätsmedizin Berlin,
40 Germany

41

42

43 Running title: Recommendations on terminology for carious tissue removal and caries
44 management

45 Keywords: dental caries; excavation; minimally invasive dentistry; caries management

46 Corresponding author: Prof. Nicola Innes
47 Paediatric Dentistry
48 Dundee Dental Hospital and School,
49 University of Dundee,
50 Park Place, Dundee, UK
51 DD1 4HN

52
53 Tel.: +44 (0)1382 381631

54 Email: n.p.innes@dundee.ac.uk

55

56 **Abstract**

57 Variation in the terminology used to describe clinical management of carious lesions has
58 contributed to a lack of clarity in the scientific literature and beyond. The International Caries
59 Consensus Collaboration (ICCC), present issues around terminology, a rapid review of current
60 words used in the literature for caries removal techniques and present agreed terms and
61 definitions, explaining how these were decided.

62 Dental caries is the name of the disease and the carious lesion is the consequence and
63 manifestation of the disease; the signs or symptoms of the disease.

64 The term dental caries management should be limited to situations involving control of the
65 disease through preventive and non-invasive means at a patient level, whereas carious lesion
66 management controls the disease symptoms at tooth level.

67 Whilst it is not possible to directly relate the visual appearance of carious lesions' clinical
68 manifestations to the histopathology, we have based the terminology around clinical
69 consequences of disease (soft, leathery, firm and hard dentine). Approaches to carious tissue
70 removal are defined. Selective Removal of Carious Tissue includes Selective Removal to Soft
71 Dentine and Selective Removal to Firm Dentine. Stepwise Removal involves Stage 1
72 "Selective Removal to Soft Dentine" then Stage 2 "Selective Removal to Firm Dentine" 6-12
73 months later. Non-selective Removal to Hard Dentine was formerly known as "complete"
74 caries removal (this technique can no longer be recommended).

75 Adoption of these terms, around managing dental caries and its sequelae, will facilitate
76 improved understanding and communication between researchers, within dental educators
77 and the wider clinical dentistry community.

78

79

80 Introduction

81 The International Caries Consensus Collaboration (ICCC), a group of 21 cariology experts
82 from 12 countries, met in Leuven, Belgium in February 2015 to discuss issues of relevance to
83 cariology researchers, dental educators and the clinical dentistry community. The goal was to
84 reach consensus on recommendations for managing carious lesions and the terminology
85 around this management, based on the best current scientific evidence, through discussion
86 and then consultation. In 2004, a series of papers related to the outcomes of an International
87 Consensus Workshop on Caries Clinical Trials (Pitts and Stamm 2004) were published, their
88 first goal being to "critically review modern caries definitions and measurement concepts".
89 Definitions, concepts and terminology as well as evidence to support newer approaches for
90 treating carious lesions, have advanced since then, and the ICCC felt there was a need to
91 clarify them based on available contemporary evidence and expertise.

92 Dental caries is the name of a disease where an ecologic shift within the dental biofilm
93 environment, driven by frequent access to fermentable dietary carbohydrates, leads to a move
94 from a balanced population of micro-organisms (of low cariogenicity) to a high cariogenic
95 (more aciduric and acidogenic) microbiological population and to an increased production of
96 organic acids. This promotes dental hard tissue net mineral loss and results in a carious lesion
97 (Fejerskov et al. 2008).

98 This report from the ICCC, deals with the terminology around carious tissue removal, lays out
99 the background to the issues around terminology including a scoping review, and the initial
100 areas that were agreed to allow progression through the topic. We suggest a suite of terms
101 and definitions, based on current procedures and best evidence, explaining how these
102 decisions were made. The report defines generic dental caries terms (Table 1) where there
103 has been confusion, under the groupings of:

- 104 1) No removal of carious tissue;
- 105 2) Selective removal;
- 106 3) Stepwise removal; and
- 107 4) Non-selective removal of carious tissue.

108 One further aim is to make the nomenclature as future proof as possible by taking into account
109 the direction in which cariology is moving.

110 Background

111 150 years ago complete removal of all traces of carious tooth tissue within a carious lesion
112 was considered the gold standard, with the added "extension for prevention" tenet being
113 invoked to ensure that restoration margins were placed on areas of the tooth that are less

114 vulnerable to caries. Advances in the field of cariology regarding the biofilm, together with
115 improvement in materials, have challenged this perspective. There has been an evolution,
116 gathering increasing speed over recent decades, away from removing all signs of carious
117 tissue in a tooth, towards a more minimally invasive approach (Elderton 1993; Frencken et al.
118 2012; Banerjee and Domejean 2013). Indeed, the paradigm shift in carious lesion treatment,
119 where it is appreciated that only infected and not affected dentine requires removal (Fusayama
120 1997) has occurred. Choices for managing a carious lesion cover a spectrum of options from
121 complete surgical excision, where no part of the visible carious tissue is left in the tooth before
122 a restoration is placed, to the opposite extreme, removing none of the carious tissue at all,
123 and using non-invasive methods to prevent progression of the lesion (Ricketts et al. 2013;
124 Green et al. 2015).

125 The alternatives to ‘conventional complete caries removal’ have been tested by different
126 research groups over the last few decades through clinical trials and have been adopted, to
127 varying degrees, as standard treatment by dental schools and clinicians in many countries
128 (Innes et al. 2013; Frencken 2014; Kidd et al. 2015). However, there is inconsistency in the
129 terminology for, and definitions that lie behind these approaches. These inconsistencies have
130 developed naturally alongside the investigation of new interventions, and as a result of
131 different research groups describing and naming interventions as they have been investigated.
132 As is common in evolving fields of research, some of this research has taken place in parallel.
133 Partly because of the sensitive nature of research development, but also simply as a result of
134 a scarcity of opportunity for discussion, different terms have evolved. The lack of overt and
135 planned communication within the research, teaching and clinical practice communities has
136 resulted in some of the variations now seen in use of terminology and procedural definitions.
137 For some procedures that seem to be very similar from the descriptions in research papers,
138 different groups use distinctly different names. One particular definition of a procedure can
139 have several names; for example, Franzon et al. (2014) used the term “one-step excavation”
140 to describe an end result similar to that of Hesse’s partial caries removal with “Excavation ...
141 [to] ... hardened, dried dentin with a leathery consistency” (Hesse et al. 2011). Groups that
142 work together may know what they are referring to, but the wider audiences can misinterpret
143 what is being said – especially where a single word is used to designate a procedure, without
144 further opportunity to describe what is being meant. Conversely, but leading to equally
145 confusing scenarios, for procedures which seem to differ from their descriptions, the same
146 name, or similar ones are used by different groups. So one name holds a variety of definitions.
147 For example, with selective caries removal, Maltz et al. (2012) describes this as “Partial
148 removal of the soft carious tissue from the cavity floor by hand excavator (only disorganized
149 dentine was removed)” whereas Hesse and co-workers (2014), in their protocol step that
150 involves partial caries removal states that the “caries lesion [was] completely removed in the

151 enamel/dentin junction, and dentinal caries lesion partially removed with hand instruments
152 until the dentin started to become ‘firm and leathery’” and in the first stage of stepwise caries
153 removal Bjørndal et al. (2010) talk about “removal of the superficial necrotic and demineralized
154 dentin with complete excavation of the peripheral demineralized dentin, avoiding excavation
155 close to the pulp. When a temporary restoration could be properly placed no further excavation
156 was carried out, leaving soft, wet, and discoloured dentin centrally on the pulpal wall”.

157 To communicate successfully and concisely, researchers, clinicians and educators need to
158 use consistent terminology. This will help to ensure that carious tissue removal procedures
159 are described unambiguously. One example of a very clear description of technique in a
160 research study is found in the 10-year follow-up report of the seminal Mertz-Fairhurst and co-
161 workers’ ultra-conservative caries removal study where there were two control groups with
162 conventional restorations and one intervention arm where no soft dentine was removed. “...
163 We removed all of the crumbly, opaque demineralised enamel with a bur until we reached
164 translucent sound enamel. We did not remove undermined enamel or caries below the
165 bevel.... [we] observed shreds of carious dentin or other material hanging below the bevel
166 toward the soft and wet pulpal floor of the cavity. A layer of soft and wet-looking dentine in the
167 pulpal area of the cavity remained intact, and there was absolutely no instrumentation below
168 the enamel bevel.” (Mertz-Fairhurst et al. 1998).

169 Consistency, accuracy and precision are important for terminology to be used successfully,
170 which means there has to be standardisation globally. One of the crucial aspects of this
171 consensus work is that there is widespread dissemination and uptake, and to do this, there
172 has to be agreement that these are acceptable terms, across a broad range of communities
173 and groups. The cosmopolitan nature of the ICCC means that views have been represented
174 from 12 countries. To further assist with uptake of the terminology and its dissemination, we
175 are linking with the European Organisation for Caries Research (ORCA), the International
176 Association for Dental Research (IADR) Cariology Group and the American Dental Education
177 Association (ADEA) Cariology Section Sharing of expertise, experience and joining with
178 educational forums are part of the dissemination strategy to assist the ultimate goal of uptake
179 and use of the ICCC Terminology recommendations across the spectrum of researchers,
180 clinicians and educators.

181 **How much of a problem is the current terminology? (Scoping and consensus methodology)**

182 In a methodical search for systematic reviews comparing different methods of caries removal
183 (including partial caries removal, no caries removal etc.), seven systematic reviews were
184 identified (Griffin et al. 2008; Thompson et al. 2008; Hayashi et al. 2011; Ferreira et al. 2012;
185 Ricketts et al. 2013; Schwendicke et al. 2013a; Schwendicke et al. 2013b). When these, and
186 the studies within them, were searched for the terminologies used to describe the various

187 carious lesion management strategies, 23 terms were found. These were circulated around
188 the ICCC group members, who were asked to contribute any further terms they knew were
189 used and 19 further unique new terms were added. This gave a total of 42 terms (see Table
190 2), a large number to describe essentially four different parts of the spectrum of carious lesion
191 removal/ management.

192 The terms were circulated again, and this time the ICCC group was asked to choose up to six
193 terms that they felt were most representative of the full spectrum of options for carious tissue
194 removal. Eight different approaches to naming were returned together with comments. These
195 provided the basis for the discussions at the consensus meeting.

196 Initial areas agreed before proceeding

197 Dental caries and carious lesion

198 There was full agreement that 'dental caries' (or simply 'caries') and 'carious lesion' were not
199 interchangeable terms although they are often used as such.

200 There was consensus that dental caries (the pathological process) cannot be removed and
201 only carious tissues can be removed. An alternative way of viewing this is to consider that the
202 lesion can be stabilised, either by non-invasive, or by invasive means.

203 Although it is necessary to be exact and specify the definitions for 'caries' and 'carious', it is
204 worth noting that, in the English language, the pronunciation of these words makes them
205 sound almost identical. However, in other languages this may not be the case.

206 Dental caries management

207 The ICCC group considered two terms; "*caries management*" and "*carious lesion*
208 *management*". While the term *caries management* has been used historically in different ways,
209 often to include the restoration of teeth, it was agreed that it should be limited to situations
210 involving control of the disease through preventive and non-invasive means. Therefore, caries
211 management is a term to describe the actions taken at a patient level, i.e. demineralisation
212 and plaque/biofilm being managed not for one specific surface but for the whole person e.g.
213 plaque control/toothbrushing instruction, fluoride application, dietary interventions and
214 behaviour change techniques. Caries management aims to control the disease and prevent a
215 lesion becoming clinically manifest and for those lesions detectable clinically, prevent their
216 advancement.

217 What do we call the situation in which patient level *caries management* has failed? Consider
218 two specific situations where a carious lesion needs to be managed. Firstly, an active lesion
219 that might require a non-invasive approach such as biofilm removal or, application of fluoride
220 varnish to limit progression and secondly, where a lesion is not cleansable and is vulnerable

221 to progression even in the presence of a full preventive program. In both of these cases,
222 *carious lesion management* is aimed at controlling the symptoms of the disease at a tooth
223 level. Of course, there is still a need for *caries management* to take place at a patient level in
224 order to stem the source of the problem (the cause of the cause). However, for the purposes
225 of this paper, *carious lesion management* means any procedure that involves doing something
226 to an established, non-cleansable carious lesion to stop its progression. This might involve
227 removing “none”, “some” or “all” of the carious tissues from a non-cleansable lesion.

228 **Removal of carious tissues**

229 The term *removal* was preferred to excavation, to avoid the synonymous link (in English) with
230 hand excavation instrumentation and spoon excavators. It was agreed that the word
231 *excavation* implied (albeit to a minor extent) that the process was inextricably linked to hand
232 excavation of carious lesions, and could possibly limit the generalisability of the term.

233 **Guiding principles of caries tissue removal**

234 The ICCG group agreed that the primary aim of carious tissue removal is:

- 235 • To retain the tooth and the health (sensitivity/vitality) of its pulp for as long as possible.

236 The guiding principles of carious tissue removal are:

- 237 • Preservation of dental tissues;
- 238 • Maintenance of pulpal health;
- 239 • Avoidance of pulp exposure;
- 240 • Avoidance of dental anxiety, (often considered particularly important in children but should
241 be considered for all patients);
- 242 • Provision of sound cavity margins to achieve a peripheral seal;

243 **Complete removal of carious tissues**

244 Through discussion, the group became aware that the term “*complete*”, when referring to
245 removal of carious tissues, held different meanings for different people. Whilst within the
246 group, this term was considered to mean “*removal until only leathery or firm dentine (resistant
247 to hand excavator) is left pulpally*”, there was still a widely held belief that many still considered
248 it to mean “*removal until only hard dentine is left pulpally*”. From the systematic reviews of the
249 literature that were evaluated, the group considered removal of carious lesion to leave only
250 hard dentine throughout the cavity to be over-treatment and involving removal of tooth tissue
251 that did not need to be removed (Thompson et al. 2008; Ricketts et al. 2013; Schwendicke et
252 al. 2013a). It was also agreed that although the words “firm” and “hard” are subjective, they
253 may still be the best terms available.

254 Terminology for approaches to carious tissue removal

255 In describing the clinical manifestations of caries, it would be ideal to relate the visual
256 appearance directly to what is taking place histo-pathologically (Ogawa et al. 1983; Ngo et al.
257 2006; Wambier et al. 2007; Chibinski et al. 2013; Corralo and Maltz 2013). However, this is
258 not straightforward. Histo-pathological micro- and ultra-structural investigations of the
259 relationship between the visual appearance of carious tooth tissue and parameters such as
260 bacterial invasion, degree of demineralisation, and softness of dentine etc. have been central
261 to developing an understanding of the caries process. One historical example of
262 misinterpretation of histo-pathology leading to over-excavation, was the belief that early lateral
263 spread of demineralised dentine, undermining sound subjacent enamel, led to cavitation of
264 enamel (Silverstone and Hicks 1985). To manage this clinically, early operative intervention
265 was suggested, including the concept of the tunnel preparation (Wilson and McLean 1988).
266 However, more recent research has clarified the structural inter-relations confirming that the
267 spread of contaminated dentine is a *sequelae* of the clinically exposed dentine lesion (Bjørndal
268 and Thylstrup, 1995; Ekstrand et al. 1998). The lateral contamination of dentine appears
269 strictly related to stages of retrograde demineralisation of enamel (Bjørndal and Kidd 2005)
270 i.e. demineralisation of the enamel originates at the enamel-dentinal junction as a result of
271 bacterial metabolic activity within the dentinal lesion. Interestingly, the increasing use of clinical
272 magnification technologies has led to these so-called 'histo-pathological' features being
273 visible at the clinical level. Traditionally, these histological terms are less helpful when
274 communicating to dentists in clinical settings and attempting to describe the degree to which
275 carious tissues should be removed. In addition, it was felt that some of the terms such as
276 "infected" were outdated and conveyed the idea that dental caries was a communicable
277 disease. The terms shown in Figure 1, for the clinical (tactile) manifestations of carious
278 dentine, were agreed and we have attempted to link the clinical consequences to the
279 histological terms as far as possible. Table 1. expands on this by showing these agreed terms
280 and their relationship to previously used terms.

281 Definitions for different clinical presentations of dentine (soft, leathery, firm and hard)

282 In material sciences, hardness can be characterised by the ability of a harder material to make
283 a mark or to scratch a softer one. The force necessary to cause the scratch is also important.
284 For practical purposes, a combination of these is probably the best way for the clinical dentist
285 to determine how 'soft' or 'hard' dentine is and some guidance is given below to describe the
286 physical properties that are associated with different states of dentine.

287 Soft dentine

288 Soft dentine will deform when a hard instrument is pressed onto it, and can be easily scooped
289 up (e.g. with a sharp hand excavator) with little force being required.

290 **Leathery dentine**

291 Although the dentine does not deform when an instrument is pressed onto it, leathery dentine
292 can still be easily lifted without much force being required. There may be little difference
293 between leathery and firm dentine with leathery being a transition on the spectrum between
294 soft and firm dentine.

295 **Firm dentine**

296 Firm dentine is physically resistant to hand excavation and some pressure needs to be exerted
297 through an instrument to lift it.

298 **Hard dentine**

299 A pushing force needs to be used with a hard instrument to engage the dentine and only a
300 sharp cutting edge or a bur will lift it. A scratchy sound or 'cri dentinaire' can be heard when a
301 straight probe is taken across the dentine.

302 **Definitions of approaches to carious tissue removal**

303 **Atraumatic Restorative Treatment (ART)**

304 ART was agreed to mean a specific technique, which encompassed a mechanism for carious
305 lesion management using hand instruments only, through removing soft, completely
306 demineralised enamel and dentine until firm resistance is felt (See Selective Removal of
307 Carious Tissue below). The cavity is then restored and available pits and fissures are sealed
308 with an adhesive dental material, usually a high-viscosity glass-ionomer cement. For deep
309 lesions (reaching into the inner pulpal $\frac{1}{3}$ of dentine on radiograph) some soft carious tissue
310 should be left on the pulpal wall to avoid pulp exposure. Therefore the decision to carry out
311 selective removal to firm dentine or to soft dentine (see later) is related to cavity depth and the
312 possibility of pulp exposure.

313 **No Removal (no dentine carious tissue removal)**

314 There are a variety of procedures where no dentine carious tissue removal takes place.
315 Although diverse in the methods for carrying them out, these procedures effectively serve the
316 same purpose – to control the carious lesion without removing any of the diseased dentine
317 tissue. The following techniques have been included under the "No carious tissue removal"
318 banner.

319 **Resin or Glass Ionomer Sealant Materials**

320 Pit and fissure therapeutic sealant materials (resin or high-viscosity glass-ionomer cements)
321 can be placed over enamel and dentine carious lesions. However, particularly with unfilled
322 resin, mechanical properties are limited for filling and covering micro-cavities in enamel. There
323 are also theoretical concerns about the materials' abilities to resist forces occlusally when
324 there is a considerable amount of soft dentine beneath the weakened enamel (the 'trampoline'
325 effect). Therefore, the extent of the lesions where these materials can be used may be limited,
326 pending evidence, to lesions that are confined (on a radiograph) to the outer 1/3 of dentine.

327 **The Hall Technique**

328 This is a specific procedure for primary molars where a preformed metal (stainless steel)
329 crown is fitted over the tooth to seal dentine carious lesions. The crown is cemented using
330 glass ionomer cement, over a primary molar tooth and carious lesion with no tooth preparation
331 or carious lesion removal. It is usually indicated for approximal lesions. The crown effectively
332 seals the dentine carious lesion and slows down or prevents its progression to the dental pulp
333 allowing the primary molar to exfoliate without pain or infection.

334 **Non-Restorative Cavity Control**

335 Other names for techniques (although each slightly different) that would be encompassed
336 within this strategy include non-operative caries treatment and prevention (NOCTP) (Vermaire
337 et al. 2014), non-restorative caries treatment (NRCT) (Lo et al. 1998; Gruythuysen 2010; Mijan
338 et al. 2014) and slicing preparations.

339 This is a group of techniques that are broadly similar in that they aim to achieve arrest of a
340 carious lesion using a package of care, through caries management at a patient level. They
341 aim to prevent further loss of tooth tissue through caries progression in a cleansable cavity by
342 successful instigation of an intensive preventive regimen that includes plaque removal through
343 toothbrushing with a fluoridated toothpaste and/or application of fluoride varnish. From a
344 carious lesion perspective, it may be necessary to alter the shape of the cavity by opening the
345 cavity margins, to allow it to be cleansable and thus might involve some operative although
346 not restorative intervention. These methods tend to be particularly applied to primary teeth but
347 have a role in the permanent dentition, for example in root carious lesions.

348 **Selective Removal of Carious Tissue**

349 Terms used previously for non-selective and selective removal of carious tissues have
350 commonly included; 'complete' and 'incomplete' excavation of carious lesions. These describe
351 the result at the end of the carious tissue removal process. There are three problems with
352 these terms:

- 353 1. The criteria that demarcate the extent to which carious tissues are removed have not been
354 defined or agreed; should this be “free from bacteria”, “demineralised dentine”,
355 “discoloured dentine” or “soft dentine”?;
- 356 2. There are no commonly used and easily accessible technologies available to reliably
357 assess any of these criteria in a clinical setting, although it is acknowledged that this might
358 change in the future; and
- 359 3. If clinical assessments are re-evaluated using more advanced techniques (measurement
360 of bacterial load or mineral loss), based on the findings of previous research, it is most
361 likely that areas of dentine will be found where there is incompletely removed carious
362 tissue after attempted complete removal and vice versa.

363 Thus, we felt it made more sense to use procedural definitions to describe exactly what has
364 been *done* instead of measuring what we attempted to *achieve*. Using this rationale, the group
365 agreed on the term Selective Removal. In Selective Removal, different excavation criteria are
366 used when assessing the periphery of the cavity to the area in close proximity to the pulp. The
367 periphery of the cavity should be surrounded by ‘sound’ enamel to allow the best adhesive
368 seal. The peripheral dentine should be hard – with similar tactile characteristics to sound
369 dentine, such as a scratching noise when scraping the surface with a sharp hand excavator
370 or dental probe. However, firm carious tissue should be left towards the pulpal aspect of the
371 cavity, with enough of it removed to allow a durable bulk of restoration to be placed, whilst
372 avoiding pulp exposure. For deep lesions (extending beyond the inner (pulpal) third or quarter
373 of the dentine radiographically) Selective Removal should be *to soft dentine* (the main aim is
374 **not** to expose or irritate the pulp, provided that there are no clinical symptoms of pulp
375 inflammation present). For less deep lesions Selective Removal should take place *to firm*
376 *dentine* pulpally (this is likely to be necessary to allow adequate depth for the restorative
377 material bulk).

378 There were other reasons that the term Selective Removal was supported. The group agreed
379 there was an advantage to using terms that had not yet been used in the literature. This was
380 the case here where there were multiple terms for a single procedure used across different
381 groups and where the definition behind them was not clear. In addition, the negative
382 association of the terms “partial” and “incomplete”, which implied that the whole, required
383 treatment had not been carried out and that treatment was sub-optimal, were considered
384 disadvantageous in supporting the procedures’ adoption and acceptance as standard
385 techniques.

386 A description of these terms is found below.

387 **Selective Removal to Soft Dentine**

388 Selective Removal to Soft Dentine in deep lesions means leaving soft carious dentine in the
389 pulpal aspect of the cavity. Peripheral enamel and dentine should be hard at the end of
390 excavation to allow the best adhesive seal. This technique has previously been known as
391 partial caries, one-step, ultra-conservative or incomplete caries removal. A sharp hand
392 excavator can be used to check the softness/hardness of the remaining dentine, remembering
393 that soft dentine will deform when an instrument is pressed onto it and little force would be
394 required to lift it.

395 **Selective Removal to Firm Dentine**

396 In Selective Removal to Firm Dentine, the aim is to excavate to leathery or firm dentine
397 (physically resistant to hand excavator) in the pulpal aspect of the cavity. This is the
398 contemporary understanding of how much should be removed if the entire carious –
399 CONTAMINATED but not the DEMINERALISED dentine, which can be remineralised, (Fig. 1)
400 is aimed at being removed. It is acknowledged that there are not easily accessible or widely
401 used means to tell when contaminated tissue has been removed and to determine when what
402 is seen in the cavity is only demineralised dentine. However, although somewhat subjective,
403 the tactile sense of reaching *firm* dentine on the pulpal floor rather than aiming for *hard* dentine
404 is probably the best guide that can be given.

405 **Stepwise Removal**

406 Certain terms were felt to be in fairly common use, had less variability in their definition and
407 understanding and were well accepted. It was therefore considered to be advantageous to
408 adopt these as standard with just a clear and unambiguous explanation of the definition behind
409 them. This was the case for Stepwise Removal (Bjørndal et al. 1997; Bjørndal and Larsen,
410 2000; Paddick et al. 2005).

411 Stepwise Removal involves “Selective Removal to Soft Dentine” at Stage 1, followed 6-12
412 months later by “Selective Removal to Firm Dentine” for Stage 2

413 Stage 1 has the same carious tissue removal aims as “Selective Removal to Soft Dentine”
414 with completely demineralised carious tissue, still soft, being left pulpally but where there is
415 removal of enough carious tooth tissue to place a durable restoration whilst avoiding pulp
416 exposure. The periphery of the cavity should be hard – with similar appearance and tactile
417 characteristics to sound dentine. A provisional restoration is placed with a restorative material
418 that is considered suitable to last for up to 12 months. The subsequent removal of this
419 provisional restoration should then be followed by the “Selective Removal to Firm Dentine”
420 pathway with placement of a definitive restoration aiming for longevity. This technique has
421 previously been also known as “two-step excavation”.

422 **Non-selective Removal to Hard Dentine**

423 Non-selective Removal to Hard Dentine was formerly known as ‘complete excavation’ or
424 ‘complete caries removal’ and is no longer recommended as an approach for carious tissue
425 removal. It is only mentioned here for completeness. It is the approach to carious tissue
426 removal that was accepted in the past and is now considered over-treatment. The aim was to
427 remove soft carious tissue to reach hard dentine resembling healthy dentine in all parts of the
428 cavity, including pulpally. For the pulpal area, Bjørndal describes ‘complete caries excavation’
429 as “leaving only central yellowish or greyish hard dentin (equal to the hardness of sound
430 dentin, as judged by gentle probing).” (Bjørndal et al. 2010).

431 However, for deep caries lesions (reaching into the inner pulpal ⅓ of dentine on radiograph),
432 ‘complete caries excavation’ is now considered likely to result in detriment to the tooth through
433 exposure of the pulp, indirect damage to the pulp from irritation passing through the thin
434 remaining dentine thickness or from weakening the tooth’s structural integrity unnecessarily
435 (Ricketts et al. 2013; Schwendicke et al. 2013a). This approach is no longer recommended.
436 However, for shallow carious lesions (involving the outer pulpal third of dentine on radiograph),
437 Non-selective Removal to Hard Dentine may not be much different from Non-selective
438 Removal to Firm Dentine.

439 **Summary**

440 We have presented here a comprehensive list of terms to encompass the full spectrum of
441 carious tissue removal options following a process of consensus and consultation. However,
442 other areas remain where there is no standardised terminology or where there are subjective
443 terms that are commonly used such as ‘invasive’, ‘restorative’ and ‘intervention’ and we have
444 had to resort to using some of these here and in the parallel paper to this one on
445 recommendations for managing carious lesions (Schwendicke et al. 2016). These will perhaps
446 form the next stage of standardisation but in the meantime there is a need to facilitate
447 dissemination – this is an inextricable and essential component of consensus within the
448 specialty if the advantages of the consensus terminology are to be maximised.

449 **Declaration of Interests**

450 The corresponding author formally requested a declaration of possible conflicts of interest
451 from each of the consensus conference members. Declaration of interest at the organisational
452 and individual levels are available from the lead author. The conference was kindly sponsored
453 by GC Europe (Leuven, Belgium), DMG (Hamburg, Germany), 3M Espe (Seefeld, Germany)
454 and Dentsply DeTrey (Konstanz, Germany). The sponsors had no role in design or conduct of
455 the conference or the content of this manuscript, and were not present during the conference.
456 Travel to the meeting and accommodation for LB, WB, SD, EK, MM, DM, KvL, AB, GC, MF,

457 SL, EL, VM, BN, AS, CS and AZ were supported by the sponsors. No honoraria were given to
458 any of the participants.

459 **Acknowledgements**

460 ICCC would like to thank Lisbet Brike and Amy Caldwell-Nichols for organising travel and
461 accommodation for the conference in Leuven and to Amy Caldwell-Nichols for additional
462 document and manuscript preparation support. Thank you also to GC for the use of their
463 premises in Leuven.

464 Grateful thanks also go to Professor Edwina Kidd, for her presentation, invaluable discussions
465 at the meeting in Leuven and input into improving this manuscript and finally, for so generously
466 sharing their wisdom and experience. We thank Professor Wolfgang Buchalla for his
467 contribution to the meeting and discussions on the composition of the manuscripts and respect
468 his decision not to support their content through authorship.

469 **Authors contribution**

470 Initiated and organized the consensus process: JF, FS, NI

471 Prepared abstracts for the meeting and held presentations: LB, MM, DM, DR, KvL, FS

472 Contributed to the workshop and the consensus process before and after the workshop: all
473 authors.

474 Wrote the initial draft of the manuscript: NI, JF, FS

475 Read, amended and approved the manuscript: all authors.

476 **References**

- 477 Banerjee A, Domejean S. 2013. The contemporary approach to tooth preservation: minimum
478 intervention (MI) caries management in general practice. *Prim Dent J.* 2(3):30-37.
- 479 Bjørndal L, Thylstrup A. 1995. A Structural analysis of approximal enamel caries lesions and
480 subjacent dentin reactions. *Eur J Oral Sci.* 103(1):25-31.
- 481 Bjørndal L, Larsen T, Thylstrup A. 1997. A clinical and microbiological study of deep carious
482 lesions during stepwise excavation using long treatment intervals. *Caries Res.* 31(6):411-417.
- 483 Bjørndal L, Larsen T. 2000. Changes in the cultivable flora in deep carious lesions following a
484 stepwise excavation procedure. *Caries Res.* 34(6):502-508.
- 485 Bjørndal L, Kidd EA. 2005. The treatment of deep dentine caries lesions. *Dent Update.* 32(7):
486 402-4, 407-410.
- 487 Bjørndal L, Reit, C, Bruun G, Markvart M, Kjældgaard M, Näsman P, Thordrup M, Dige I,
488 Nyvad B, Fransson H et al. 2010. Treatment of deep caries lesions in adults: randomized
489 clinical trials comparing stepwise vs. direct complete excavation, and direct pulp capping vs.
490 partial pulpotomy. *Eur J Oral Sci.* 118(3):290-297.
- 491 Chibinski AC, Reis A, Kreich EM, Tanaka JL, Wambier DS. 2013. Evaluation of primary
492 carious dentin after cavity sealing in deep lesions: A 10- to 13-month follow-up. *Pediatr Dent.*
493 35(3):E107-112.
- 494 Corralo DJ, Maltz M. 2013. Clinical and ultrastructural effects of different liners/restorative
495 materials on deep carious dentin: A randomized clinical trial. *Caries Res.* 47(3):243-250.
- 496 Elderton RJ. 1993. Overtreatment with restorative dentistry: when to intervene? *Int Dent J*
497 43(2):17–24
- 498 Ekstrand KR, Ricketts DN, Kidd EA. 1998. Do occlusal carious lesions spread laterally at the
499 enamel-dentin junction? A histopathological study. *Clin Oral Investig.* 2(1):15-20.
- 500 Fejerskov O, Larsen MJ. 2015. Demineralization and remineralisation: the key to
501 understanding clinical manifestations of dental caries. In: Fejerskov O, Nyvad B, Kidd E.
502 (eds). *Dental caries: The disease and its clinical management.* 3rd edn. Oxford, Wiley
503 Blackwell. p 160-169.
- 504 Ferreira, J.M., Pinheiro, S.L., Sampaio, F.C., de Menezes, V.A. 2012. Caries removal in
505 primary teeth--a systematic review. *Quint Int.* 43(1);e9-15.
- 506 Franzon, R, Guimaraes LF, Magalhaes CE, Haas AN, Araujo FB. 2010. Outcomes of one-
507 step incomplete and complete excavation in primary teeth: A 24-month randomized controlled
508 trial. *Caries Res.* 48(5):376–383.
- 509 Frencken JE, Peters MC, Manton DJ, Leal SC, Gordan VV, Eden E. 2012. Minimal intervention
510 dentistry for managing dental caries - a review: Report of a FDI task group. *Int Dent J.*
511 62(5):223-243.
- 512 Frencken JE. 2014. The State-of-the-Art of ART Restorations. *Dent Update.* 41:218-224.
- 513 Fusayama T. 1997. The process and results of revolution in dental caries treatment.
514 *International dental journal.* 47(3):157-166.
515
- 516 Green D, Mackenzie L, Banerjee A. 2015. Minimally invasive long term management of direct
517 restorations: The “5rs”. *Dent Update.* 42:413-426.
518
- 519 Griffin SO, Oong E, Kohn W, Vidakovic B, Gooch BF, Bader J, et al. 2008. The effectiveness
520 of sealants in managing caries lesions. *J Dent Res.* 87(2):169-174.

521
522 Gruythuysen R. 2010. Non-restorative cavity treatment. Managing rather than masking caries
523 activity. *Nederlands tijdschrift voor tandheelkunde*. 117(3):173-180.
524

525 Hayashi, M., Fujitani, M., Yamaki, C., Momoi, Y. 2011. Ways of enhancing pulp preservation
526 by stepwise excavation - A systematic review. *J Dent*. 39(2);117-121.

527 Hesse D, Bonifácio CC, Mendes FM, Braga MM, Imparato JCP, Raggio DP. 2014. Sealing
528 versus partial caries removal in primary molars: A randomized clinical trial. *BMC Oral*
529 *Health*.14:58.

530 Innes NPT, Evans DJP. 2013. Modern approaches to caries management of the primary
531 dentition. *Brit Dent J*. 214(11):559-566.

532 Kidd EAM, Bjørndal L, Fejerskov O. 2015. Caries removal and the pulpo-dental complex. In:
533 Fejerskov O, Nyvad B, Kidd E. (eds). *Dental caries: The disease and its clinical management*.
534 3rd ed. Oxford, Wiley Blackwell. p 376-386.

535 Lo EC, Schwarz E, Wong MC. 1998. Arresting dentine caries in Chinese preschool children.
536 *Int J Paed Dent*. 8(4):253-260.

537 Lula ECO, Almeida Jr LJS, Alves CMC, Monteiro-Neto V, Ribeiro CCC. 2011. Partial caries
538 removal in primary teeth: Association of clinical parameters with microbiological status. *Caries*
539 *Res*. 45(3):275-280.

540 Maltz M, Garcia R, Jardim JJ, De Paula LM, Yamaguti PM, Moura MS, Garcia F, Nascimento
541 C, Oliveira A, Mestrinho HD. 2012. Randomized Trial of Partial vs. Stepwise Caries Removal:
542 3 years Follow-up. *J Dent Res*. 91(11):1026-1031.

543 Mertz-Fairhurst EJ, Curtis JW Jr, Ergle JW, Rueggeberg FA, Adair SM. 1998.
544 Ultraconservative and cariostatic sealed restorations: Results at year 10. *J Am Dent Assoc*.
545 129:55-66.

546 Mijan M, de Amorim RG, Leal SC, Mulder J, Oliveira L, Creugers NH, Frencken JE. 2014. The
547 3.5-year survival rates of primary molars treated according to three treatment protocols: A
548 controlled clinical trial. *Clin Oral Investig*. 18(4):1061-1069.

549 Ngo HC, Mount G, Mc Intyre J, Tuisuva J, Von Doussa RJ. 2006. Chemical exchange between
550 glass-ionomer restorations and residual carious dentine in permanent molars: An in vivo study.
551 *J Dent*. 34(8):608-613.

552 Ogawa K, Yamashita Y, Ichijo T, Fusayama T. 1983. The ultrastructure and hardness of the
553 transparent of human carious dentin. *J Dent Res*. 62(1):7-10.

554 Paddick JS, Brailsford SR, Kidd EA, Beighton D. 2005. Phenotypic and genotypic selection of
555 microbiota surviving under dental restorations. *Appl Environ Microbiol*. 71(5):2467-2472.

556 Pitts NB, Stamm JW. 2004. International Consensus Workshop on Caries Clinical Trials (ICW-
557 CCT)--final consensus statements: agreeing where the evidence leads. *J Dent Res*. 83(C
558 Suppl):C125-128.

559 Ricketts D, Lamont T, Innes NP, Kidd E, Clarkson JE. 2013. Operative caries management in
560 adults and children. *The Cochrane Database of Systematic Reviews*. 28:CD003808.

561 Schwendicke F, Meyer-Lückel H, Dorfer C, Paris S. 2013a. Failure of incompletely excavated
562 teeth - a systematic review. *J Dent*. 41(7):569-580.

- 563 Schwendicke, F., Dörfer, C.E., Paris, S. 2013b Incomplete caries removal: A systematic
564 review and meta-analysis. *J Dent Res.* 92(4):306-314.
- 565 Schwendicke F, Frencken JE, Bjørndal L, Maltz M, Manton D, Ricketts D et al. 2016. Managing
566 carious lesions: Consensus recommendations on carious tissue removal. *Adv Dent Res.*
- 567 Silverstone LM, Hicks MJ. 1985. The structure and ultrastructure of the carious lesion in
568 human dentin. *Gerodontology.* 1(4):185-193.
- 569 Vermaire JH, Poorterman JHG, Van Herwijnen L, Van Loveren C. 2014. A Three-Year
570 Randomized Controlled Trial in 6-Year-Old Children on Caries-Preventive Strategies in a
571 General Dental Practice in the Netherlands. *Caries Res.* 48(6):524-533.
- 572 Thompson V, Craig RG, Curro FA, Green WS, Ship JA. 2008. Treatment of deep carious
573 lesions by complete excavation or partial removal A critical review. *J Am Dent Assoc.*
574 139(6):705-712.
- 575 Wambier DS, dos Santos F, bio A, Guedes-Pinto AC, Jaeger RG, Simionato MRL. 2007.
576 Ultrastructural and microbiological analysis of the dentin layers affected by caries lesions in
577 primary molars treated by minimal intervention. *Pediatr Dent.* 29(3):228-234.
- 578 Wilson AD, McLean JW. 1988. Glass-ionomer cement. Chicago. Quintessential Publishing
579 Company. p. 179-220.
- 580

581 Table 1. Overview of carious tissue removal/management terminology and groupings.

Type of carious tissue removal	Previous names/further detail	Short descriptions	Indications for non-cleansable dentine carious lesions
Atraumatic Restorative Treatment (ART)	A specific technique for carious lesion management using hand instruments only	<ul style="list-style-type: none"> - Carious tissue removal using hand instruments only. - Pulpally; excavate to firm dentine in shallow lesions and to soft dentine in deep lesions. - Restore cavity and seal available pits and fissures with adhesive dental material, usually a high-viscosity glass-ionomer cement. 	Primary & permanent teeth Shallow and moderate [†] dentine carious lesions to allow adequate depth for a durable restoration
No removal		- No dentine carious tissue removal.	
Fissure sealant including 'ART sealants' (therapeutic)		- Fissure sealants, place sealants (resins) or glass-ionomer cement over clinically intact enamel or enamel with signs of early breakdown. This can also be suitable where there is a micro-cavitation but the material is considered to have adequate mechanical properties to bridge any enamel breaches.	Primary & permanent teeth Shallow and moderate [†] carious lesions that appear non-cavitated clinically, radiographically they might extend into dentine.
Hall Technique		- Preformed (stainless steel) crown is cemented over the primary molar tooth to seal dentine carious lesions	Primary teeth Moderate [†] and deep* non-cavitated and cavitated proximal carious lesions, radiographically – 'clear' band of dentine between carious lesion and pulp. Permanent teeth Not indicated.
Non-Restorative Cavity Control	Non-Restorative Caries Treatment, Non-Operative Caries Treatment and Prevention, Slicing Technique	<ul style="list-style-type: none"> - Cavitated dentine carious lesions are transformed to cleansable forms that can be cleaned by the patient or parent/carer with a toothbrush. - May or may not be supported by regular fluoride varnish application or placement of glass-ionomer based material. 	Primary & permanent teeth Cavitated dentine carious lesions that can be made cleansable; might not be restorable (for permanent teeth, might also be suitable for root surface caries).
Selective Removal to Soft Dentine	Partial, incomplete, minimally invasive or ultraconservative caries removal	<ul style="list-style-type: none"> - Pulpally; remove carious tissue until soft dentine is reached. - Enough tissue is removed to place a durable restoration avoiding pulp exposure. - Periphery of cavity; clean to hard dentine (similar to sound dentine). 	Primary & permanent teeth Deep carious lesions*.
Selective Removal to Firm Dentine	Partial caries removal, minimally invasive or incomplete caries removal	<ul style="list-style-type: none"> - Pulpally; remove carious tissue until leathery or firm dentine (resistant to hand excavator) is reached. - Periphery of cavity; clean to hard dentine (similar to sound dentine). 	Primary & Permanent teeth Shallow and moderate dentine carious lesions [†] to allow adequate depth for a durable restoration.
Stepwise Removal	Stepwise caries removal, Stepwise excavation, 2-step caries removal	<ul style="list-style-type: none"> - Pulpally; Selective Removal to Soft Dentine during 1st step – remove carious tissue until soft dentine is reached. - Enough tissue is removed to place a durable restoration avoiding pulp exposure. - Periphery of cavity; clean until hard dentine is reached (similar to sound dentine). <i>Subsequently (6-12 months)</i> - Pulpally; Selective Removal to Firm Dentine and place a long-term restoration. 	Primary teeth Not indicated – use Selective Removal to Soft dentine. Permanent teeth Deep carious lesions*.
Non-selective to Hard Dentine (not advocated)	Complete caries removal	<ul style="list-style-type: none"> - Pulpally & cavity periphery; carious tissue removal aims to remove all demineralised dentine to reach hard dentine, leaving no softened dentine. - Considered over-treatment 	Primary & permanent teeth <u>Not advocated.</u>

582
583
584
585

[†]Shallow and moderate lesions involving the outer pulpal two thirds or three quarters of dentine radiographically, or where there is no risk of pulp exposure

*Deep = radiographically involving the inner pulpal third or quarter of dentine, or with clinically assessed risk of pulpal exposure

588 Table 2. The 42 Individual terms for carious tissue removal/management techniques derived through
 589 structured literature searching and consultation within the ICCC.

590

Arrestment of caries lesion in dentin	Non-restorative caries treatment
ART	Non-restorative therapy
Atraumatic restorative treatment	Non-surgical caries management
Caries control achieved	One step complete caries removal
Complete caries removal	One-step incomplete excavation
Complete excavation	Partial caries removal
Conservative treatment of deep caries lesions	Partial excavation
Incomplete caries removal	Sealing in caries lesion
Incomplete excavation	Sealing-in caries
Indirect pulp cap	Sealing-in caries "using restorative materials/techniques" (resins, crowns, etc)
Minimally invasive caries removal	Sealing-in caries using "non-restorative caries treatment" (e.g., sealants, infiltration)
Minimally invasive indirect pulp therapy technique	Selective
Minimally invasive operative approach	Selective excavation
Minimally invasive operative caries management	Stepwise
Minimum intervention dentistry	Stepwise caries removal
No caries removal	Stepwise excavation
No dentinal caries removal	Surgical
Non-invasive management of caries lesions	Two-step complete excavation
Non-mechanical removal of carious tissue	Two-step incomplete excavation
Non-operative caries treatment and prevention	ultra-conservative treatment (cleaning sizable cavities with brush and paste in primary teeth) and small cavities restored with ART
Non-operative management of caries lesion (arrest of caries lesion)	Unselective

591

592

593

594

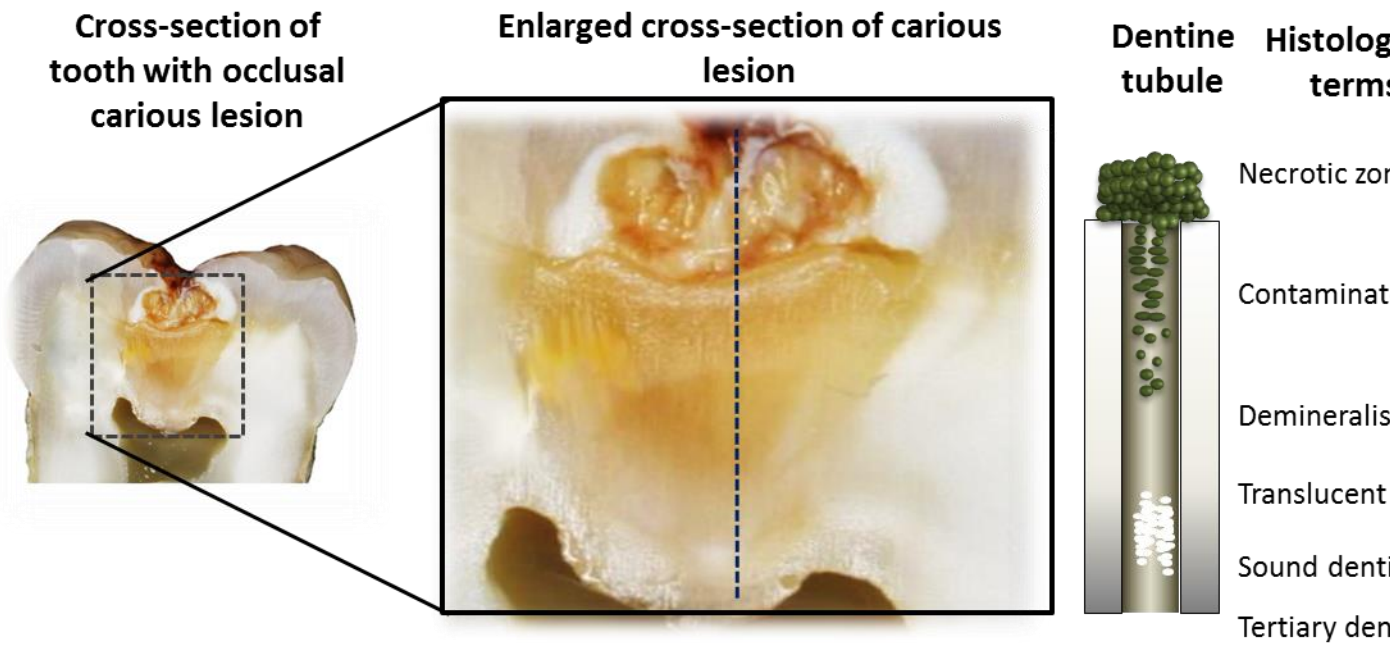


Figure 1. Diagrammatic representation of the carious lesion (after Ogawa et al.)